

## TECHNIQUE OF LAPAROSCOPIC PYELOPLASTY

THOMAS W. JARRETT

Division of Endourology, Brady Urological Institute, School of Medicine, The Johns Hopkins University,  
Baltimore, USA

### ABSTRACT

Pyeloplasty remains the gold standard therapy in the treatment of ureteropelvic junction obstruction. Laparoscopic pyeloplasty provides a minimally invasive alternative to open pyeloplasty without compromise of treatment success or durability. Presented is the surgical technique of laparoscopic pyeloplasty.

**Key words:** ureteropelvic junction, obstruction, laparoscopy, pyeloplasty  
**Braz J Urol, 26: 76-81, 2000**

### INTRODUCTION

A ureteropelvic junction (UPJ) obstruction is an impediment to urine flow at the junction of the ureter and renal pelvis that leads to progressive dilation of the collecting system. The condition can be primary or secondary and may not present until later in life. The "gold standard" therapy has been the open pyeloplasty with success rates consistently greater than 90% for all types (1). Endoscopic incision either in an antegrade or retrograde fashion provides a minimally invasive alternative, however has success rates of only 70-89% even in well-selected patients (2,3). Patients at high risk for failure include those with a large redundant renal pelvis, the presence of crossing vessels, or poor renal function (< 20%). In these cases, pyeloplasty has a clear advantage.

The first laparoscopic pyeloplasty was performed by Schuessler et al. (4) in 1993 as an alternative to standard open pyeloplasty performed through a flank incision. Initially there was some skepticism surrounding the technical feasibility, success and durability of the procedure. Recent studies however have shown overall success rates over 95% for primary obstructions (5).

### INDICATIONS AND PATIENT PREPARATION

Radiographic evidence of a UPJ obstruction in conjunction with recurrent urinary tract infections, pain, deterioration of renal function or calculus formation are unequivocal indications.

In equivocal cases, a nuclear medicine examination with lasix washout may be helpful. A urine culture is obtained pre-operatively and any infection treated with appropriate antibiotics. The presence of calyceal stones previously was a relative contraindication, however pyelolithotomy can be safely performed in the same setting. If the patient has a stone in the renal pelvis, the stone should be removed percutaneously and the patient subsequently re-evaluated for UPJ obstruction. A mild bowel preparation with clear liquids and laxative is given one day pre-op and the patient is typed and screened.

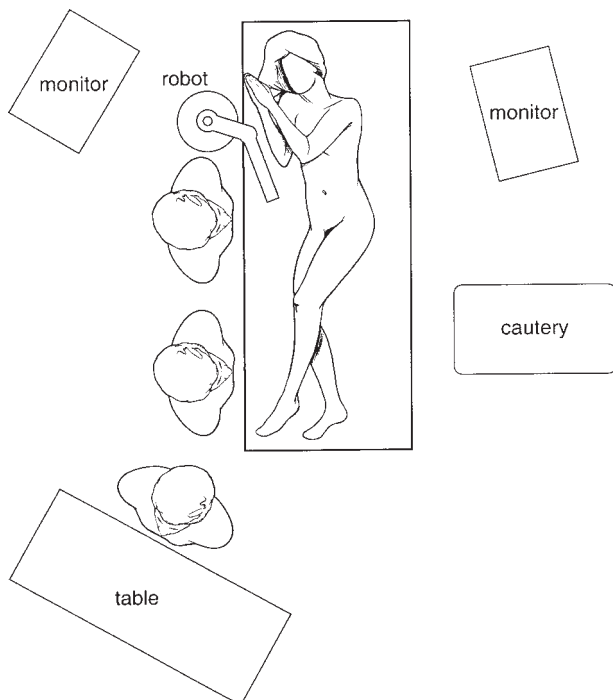
### TECHNIQUE

The patient is brought to the operating suite and cystoscopy with retrograde pyelography is performed to delineate ureteral anatomy and exclude distal stricture or filling defects due to calculus or

tumor. A ureteral double pigtail stent is then placed and correct position confirmed with fluoroscopy. We perform this portion with flexible cystoscopy with the patient supine so that minimal re-positioning is required for the next portion of the procedure. A Foley catheter is placed just prior to proceeding to the laparoscopic portion of the procedure.

### Patient Positioning

The patient is moved to the flank position with the ipsilateral side rotated up approximately 20-degrees. An axillary roll is placed, pressure points are padded and the table is flexed slightly at the hips. The patient is secured to the table using wide cloth tape at the lower extremities, hips and shoulders. This allows for the patient to be rotated from a relatively horizontal position to the flank position by simply rotating the table. The surgeon and assistant stand on the contralateral side of the table and the scrub nurse

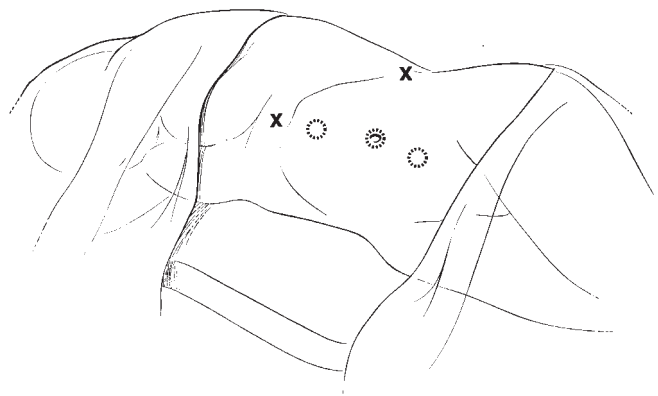


**Figure 1** – Proper positioning for laparoscopic pyeloplasty. The patient is placed in a slight flank position with the hips and shoulders rotated 15 to 20-degrees. The patient is secured so that the table can be rotated to the full flank position after trocar placement.

at the feet (Figure-1). The abdomen and flank is prepped and draped in the usual sterile fashion.

### Insufflation and Trocar Placement

Although both retroperitoneal and transperitoneal approaches have been described, the author's preference is transperitoneal due to familiarity and ease of exposure of the UPJ. Open port placement at the umbilicus or placement of the Veress needle can be performed with the patient in the horizontal position. Correct placement in the peritoneum is confirmed by aspiration with no withdrawal of air, urine, blood or fecal matter and maintenance of a low pressure (10-mm Hg) with slow insufflation. Following this step, three midline 10-12 mm trocars are placed



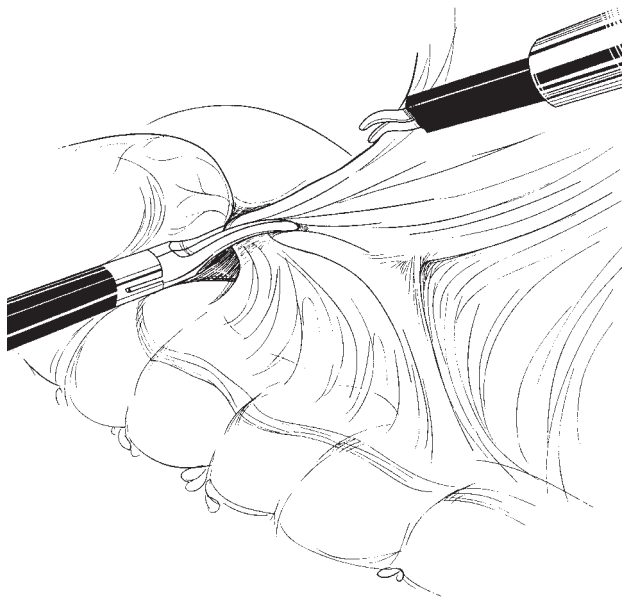
**Figure 2** – Three midline 10-12 mm trocars are placed. Accessory trocars (X) can be placed in the mid axillary line at the level of the umbilicus for retraction of adjacent organs. For right-sided procedures, a midline accessory port can be placed just below the xiphoid for retraction of the liver.

as outlined in Figure-2. Although smaller trocars can be used, this configuration allows for passage of the camera as well as any instrument through any of the ports. Accessory trocars can be placed lateral to the rectus fascia at the level of the umbilicus for use by the assistant in retraction of adjacent organs. For right-sided repairs, a small midline trocar just below the xiphoid can be used for retraction of the liver.

### Mobilization of the Colon

The patient is rotated from the horizontal to the flank position. Frequently, the hydronephrotic

kidney can be identified posterior and lateral to the colon. The posterior peritoneum overlying the kidney is divided from the upper pole to a distance approximately 3 cm below the lower pole. Care must be taken so as to not divide the lateral attachments of Gerota's fascia allowing the kidney to "flop" medially. The reno-colic ligaments are divided allowing the colon to passively move medially and provide clear exposure to the UPJ (Figure-3).



*Figure 3 – The posterior peritoneum is divided. The colon is then mobilized medially by division of the renocolic ligaments. The UPJ is frequently seen at this point as a fluid filled sack.*

### Identification of the Ureter

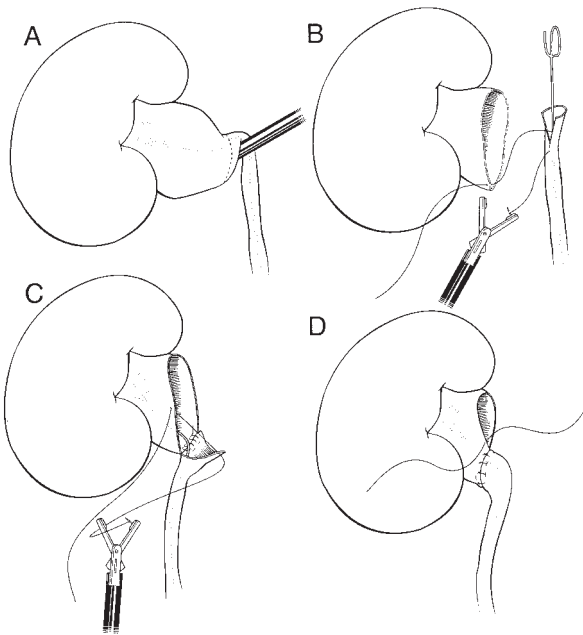
The ureter is identified by following the psoas muscle to a point just medial to the lower pole of the kidney. The ureter can be distinguished from the gonadal vessels by peristalsis and by the presence of the internal stent. If a stent had previously been placed, this part of the case may be difficult due to marked peri-ureteral inflammatory reaction. Care should be taken to not strip the peri-ureteral tissues (and blood supply) except at the level of the UPJ. Once the ureter has been identified, it is freed in a cephalad direction toward the UPJ.

A significant number of patients will have a crossing vessel, which may be inadvertently injured if not identified. At this point, the surgeon must commit to one of three following types of repairs: 1)- Anderson-Hynes dismembered pyeloplasty, 2)- Foley Y-V plasty or 3)- Fengerplasty (Heinke-Michuliz repair). Pyelolithotomy (discussed later) is performed if stones are present prior to proceeding to surgical repair.

Regardless of repair performed, the surgeon needs to ensure that the repair can be made without tension. Maneuvers to help decrease the distance between UPJ and ureter are the following: 1)- continued dissection of the UPJ and ureter (while maintaining its blood supply), 2)- freeing the kidney outside the capsule so that may be mobilized caudally and/or 3)- a nephropexy can be performed by suturing the renal capsule at the lower pole to the psoas muscle.

### Anderson- Hynes Repair

An Anderson Hynes repair can be used with any type UPJ obstruction and is the technique of choice with a crossing vessel as the ureter can be divided and transposed anteriorly. To facilitate this repair the pelvis is dissected (Figure-4) so as to allow for optimal visualization and enough mobility to allow for a tension free anastomosis with the ureter. The scissors are used to divide the ureter at the UPJ. In the presence of a crossing vessel, the ureter is transposed anteriorly. With a large redundant pelvis, a reduction needs to be performed prior to final repair. The ureter is then spatulated on its lateral aspect (facing the medial aspect of the kidney). Although free hand intra-corporeal suturing can be performed, we have found this portion of the case facilitated by use of an intra-corporeal suturing device (Endostitch, US Surgical, Norwalk, CT). Three interrupted sutures (4-0 vicryl) are initially placed to properly align the repair. The first interrupted stitch is placed from extraluminal to intraluminal at the apex of the incision of the ureter and then from intraluminal to extraluminal on the most dependent portion of the UPJ (Figure-4). The ureter is then secured at the most cephalad portion anteriorly and posteriorly in a tension free fashion to the corre-



**Figure 4 – Dismembered pyeloplasty.**

- A) UPJ obstruction due to a crossing vessel. The UPJ is dissected for optimal visualization.
- B) The UPJ is divided and the ureter transposed anteriorly if a vessel is present. The repair is started by suturing the apex of the incision in the ureter to the most dependent portion of the UPJ.
- C) A second interrupted suture is placed at the most cephalad portion of the ureter (posterior aspect) and the gaps closed with additional interrupted sutures. This step is repeated for the anterior aspect of the repair.
- D) The remaining portion of the repair is closed with a running stitch.

sponding site on the pelvis. The repair is inspected and any gaps closed with interrupted sutures. The cephalad portion of the defect is closed with a running repair (Figure-4).

### Foley Y-V Plasty

A Foley Y-V plasty repair can be used in the absence of a crossing vessel and is optimal for UPJ obstruction with a high insertion. The advantages of this repair are that it significantly reduces operative time and has less risk of devascularization of the UPJ. The success of the Y-V plasty depends on proper placement of the incision ensuring a broad-based flap of pelvis. Following incision the apex of the flap is advanced and secured with an interrupted suture ensuring no tension. The remain-

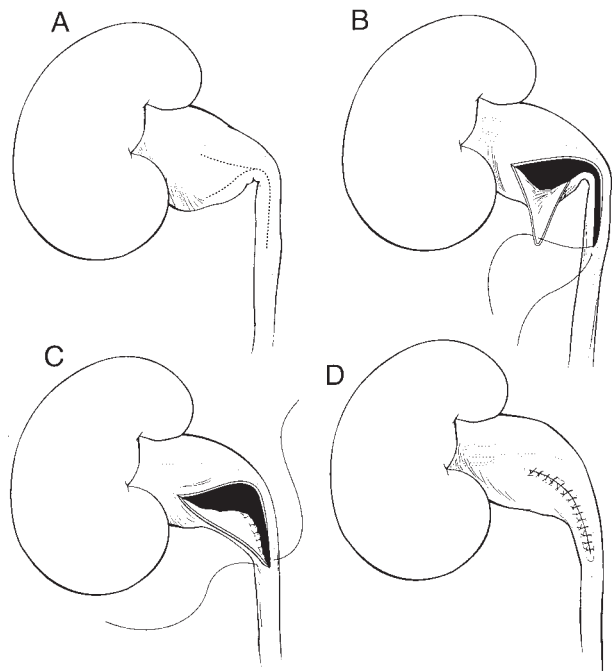
ing gaps are then closed in an interrupted fashion (Figure-5).

### Heineke-Mikulicz Repair

A Fengerplasty is technically the simplest repair and can be used with a short stricture in the absence of a crossing vessel or high insertion. With this type of repair, abnormal ureter is identified and an incision created using scissors for a distance of approximately 7 mm above and below the stenosis. The incision is then closed in a transverse fashion using interrupted sutures to bring the caudal and cephalad portions of the incision together. The remaining gaps are then closed in an interrupted fashion (Figure-6).

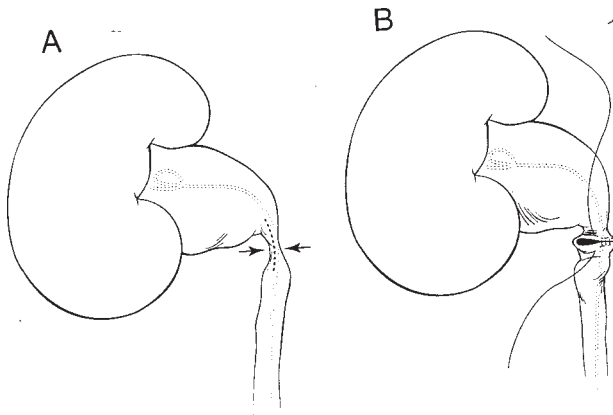
### Pyelolithotomy

Pyelolithotomy can be performed in the same setting for treatment of calyceal and non-ob-



**Figure 5 – FOLEY Y-V PLASTY**

- A) The UPJ is inspected and a broad-based flap is mapped out.
- B) The incision is created as illustrated.
- C) The tip of the flap is advanced distally on the ureter and secured with an interrupted suture. The posterior aspect of the repair is then performed with interrupted sutures.
- D) The anterior aspect of the Y is repaired to complete the procedure.



**Figure 6 – Heineke-Mikulicz Repair**

A) An incision is created as illustrated extending above and below the UPJ.

B) The incision is then closed transversely in an interrupted fashion.

structing renal stones. Review of the pre-operative intravenous urography (IVU) and a plain film just prior to the procedure is helpful in delineating the exact number and location of the stones. For pyelolithotomy, an incision is created in the renal pelvis as needed for the proposed repair (i.e. Anderson Hynes, Y-V plasty). Many times the stones can be seen and grasped under direct vision. If not readily seen or located in peripheral calyces, a flexible cystoscope is passed through the upper port site and manipulated into the renal collecting system. A tipless basket (Cooke Urologic; Spencer, Indiana) or grasper is used for stone removal. If the stones are large then lithotripsy may be necessary. One should not proceed to repair until a stone free status is ensured.

At the end of the laparoscopic pyeloplasty, a 5 mm closed suction drain is placed at the posterior axillary line and positioned just posterior to the repair site and sutured in place. Trocar sites are closed and the patient is transferred to the recovery room.

### POST-OPERATIVE CARE AND DRAIN MANAGEMENT

Strict outputs from the Foley catheter and retroperitoneal drain are recorded. If there is mini-

mal output from the retroperitoneal drain, the Foley is typically removed on post-operative day number two. The retroperitoneal drain is removed shortly thereafter if there is no increase in output. If there is persistent urine drainage from the retroperitoneal drain, the patient is sent home and educated on recording the outputs. The drains are removed when the above criteria are met.

### FOLLOW-UP

The ureteral stent is removed in 4-6 weeks and an IVU is obtained two to three months post-operatively if the patient is without symptoms. Most failures will present in the first year

### COMPLICATIONS

Complications related to laparoscopic pyeloplasty and their management are similar to those with open pyeloplasty. Intra-operative complications include bleeding that might require transfusion, injury to adjacent organs (bowel, liver, spleen and pancreas), conversion to an open procedure, adhesion formation, incisional hernia, infection or deep venous thrombosis. Postoperative complications include urinoma secondary due to persistent leakage and inadequate drainage.

### COMMENTS

Laparoscopic pyeloplasty is a challenging but safe operation in the hands of an experienced laparoscopist. The advantages to the patient are optimal cosmetics, less post-operative morbidity leading to shorter hospitalization, less discomfort, and more rapid convalescence. Studies thus far indicate the approach is as efficacious as its open surgical counterpart when applied for the treatment of UPJ obstructions.

### REFERENCES

1. Scardino PT, Scardino PL: Obstruction of the Ureteropelvic Junction. In: Bergman H (ed.), *The Ureter*. New York, Springer-Verlag, p. 697, 1981.

2. Cassis AN, Brannen GE, Bush WH, Correa RJ, Chambers M: Endopyelotomy: review of results and complications. J Urol, 146: 1492-1495, 1991.
3. Van Canghai PJ, Wilmart JF, Opsomer RJ, Abi-Aad A, Wese FX, Lorge F: Long-term results and late recurrence after endoureteropyelotomy: a critical analysis of prognostic factors. J Urol, 151: 934-937, 1994.
4. Schuessler WW, Grune MT, Tecyanhuey LV, Preminger GM: Laparoscopic dismembered pyeloplasty. J Urol, 150: 1795-1798, 1993.
5. Jarrett TW, Fabrizio M: Laparoscopic Pyeloplasty : five-year experience (*manuscript in progress*).

---

*Received: June 20, 1999*

*Accepted: June 30, 1999*

---

**Correspondence address:**

Thomas W. Jarret, M. D.  
Johns Hopkins Bayview Medical Center  
4940 Eastern Avenue  
Baltimore, Maryland, 21224, USA  
Fax: (0021) (1) (410) 550-3341