

CURRENT INDICATIONS FOR ENDOPYELOTOMY

PAUL J. VAN CANGH, SYLVAIN NESA, PIERRE DE GROOTE

Department of Urology, Catholic University of Louvain Medical School,
Cliniques Universitaires St Luc, Brussels, Belgium

ABSTRACT

Results of endopyelotomy fall somewhat short of contemporary open pyeloplasty (67-95% versus 95-100%). As most endopyelotomy series using different techniques achieve approximately the same results, it appears likely that selection criteria play a major role. Risk factors have been identified: the presence of vessels crossing directly the ureteropelvic junction stands out as a major prognostic factor of outcome; the degree of hydronephrosis, the type of obstruction and renal function also play a role, although of lesser importance. Long avascular strictures and major alteration of renal function clearly contraindicate the procedure. In our view, the presence of a crossing vessel should be ascertained preoperatively as it significantly influences the outcome. Modern diagnostic techniques such as spiral-computed tomography, color Doppler and endoluminal ultrasonography have replaced the more invasive procedures such as angiography.

With careful attention to operative details, endopyelotomy produces outstanding results with minimal morbidity. The present development of retrograde techniques avoiding the morbidity of a percutaneous access and achieving comparable success are promising. We believe that with better definition of the indications one will further improve the outcome and match open pyeloplasty in well selected patients: in the absence of vessels crossing the UPJ and of massively dilated renal pelvis, a 95% success rate can be expected.

Key words: ureteropelvic junction, obstruction, treatment, endopyelotomy, indications

Braz J Urol, 26: 54-63, 2000

INTRODUCTION

For many years open surgery has been recommended as the optimal therapy for ureteropelvic junction (UPJ) obstruction; of the existing operations, dismembered pyeloplasty still stands out today as the gold standard. Percutaneous surgery was developed in the early 1980's for the treatment of nephrolithiasis. Its intrinsic advantages of minimal invasiveness were rapidly perceived and applied to the management of UPJ obstruction. As of 1983 several reports of endoscopic management began to appear under various denominations, such as percutaneous pyeloplasty (1), pyelolysis, endopyelotomy (2) and endoureteropyelotomy (3). This last term "endoureteropyelotomy" was coined to underscore the impor-

tance of a combined ureteropelvic incision, as "endopyelotomy" sounded restrictive to the renal pelvis (pyelon).

The basic principle of these procedures consists of a full thickness incision of the narrow segment followed by prolonged stenting and drainage to allow regeneration of an adequate caliber ureter around the stent. This concept was first described in 1903 by the French urologist Joachin Albarran ("urétérotomie externe"), and was popularized by D. Davis in 1943 as an open procedure ("intubated ureterotomy"). Although confirmed by experimental and clinical data, this pioneer work remained under-exploited in UPJ obstruction because of the excellent results of open pyeloplasty, both procedures necessitating an open surgical approach. The devel-

opment of minimally invasive endourological techniques revived the interest in intubated ureterotomy, which could at that time be performed percutaneously. With continuing progresses in endourology, refined techniques designed to further reduce the operative morbidity were developed, such as the retrograde approaches performed either under direct endoscopic vision by ureterorenoscopy or under simple fluoroscopic control [balloon dilation (4) and rupture (5) as well as the “cutting balloon” or Acucise] (7-12).

Reported success rates for such procedures vary from 50 to 98%, but remain inferior to open pyeloplasty. Nowadays enthusiastic endourologists do not hesitate to recommend endopyelotomy as the primary procedure for every UPJ obstruction management, estimating that inherent advantages far compensate for the inferior results. There is an obvious divergence of opinion between those proponents of unselected indication of endopyelotomy and the persistent reluctance of the general urological community (13). In our view, success appears to depend more on selection factors than on the type of operation or on technical variations, thereby underscoring the importance of prognostic factors determination (14). In this paper we will review the factors influencing the outcome of endopyelotomy and from there make suggestions for the optimal indications of the procedure.

We believe that careful preoperative evaluation of risk factors is the best way to make endopyelotomy accepted as a first therapeutic option in UPJ obstruction (15,16).

SIGNIFICANT RISK FACTORS

Crossing Vessels

In our experience, the presence of vessels crossing the site of the UPJ and the degree of hydronephrosis are the most significant factors influencing the outcome of endopyelotomy. The significance of vessels crossing the ureteropelvic junction (UPJ) remains a matter of debate: their exact role in the pathogenesis of the obstruction, as well as their influence on the outcome of various therapeutic procedures are still contro-

versial. We published an extensive historical review in 1996 (17).

In 1994 we showed that crossing vessels bore a statistically significant negative influence on the outcome of endo(uretero)pyelotomy in a totally unselected prospective study enrolling 87 consecutive patients presenting with symptomatic UPJ obstruction between 1986 and 1989 (18). Sixty-seven adults underwent a systematic preoperative angiographic study and endoureteropyelotomy was performed regardless of its results. In 26/67 patients (39%), vessels were demonstrated in close contact with the site of the obstruction. The presence of crossing vessels reduced the final success rate from 86 to 42%. The degree of hydronephrosis was also a negative factor, but of lesser significance. The influence of the combination of both factors was highly significant on final outcome, with a 95% success rate when there was no crossing vessels and a moderate degree of hydronephrosis, and only 39% when crossing vessels were associated with high grade hydronephrosis (odds ratio = 28.29, 95% confidence interval 24.91; 31.66, $p < 0.001$). We later reported on the preoperative vascular surroundings in 85 patients with a follow up extending more than 12 years (mean 6.5 years) (19). The importance of these prognostic factors was confirmed: the success rate was 33% and 82% with and without crossing vessels respectively. Crossing vessels were present in only 18% of successful cases as opposed to 67% of failures. Moreover significant crossing vessels were demonstrated in 15/18 patients undergoing secondary open pyeloplasty for endopyelotomy failure; concomitant high-grade hydronephrosis was present in 13 instances. Our latest results were presented at the 17th World Congress of Endourology, and our conclusions are unchanged with 111 patients having had a detailed investigation of their vascular anatomy (Table-1) (20). As our proactive search for significant crossing vessels continues, spiral CT and color Doppler ultrasonography - either simple or contrast enhanced - have presently replaced angiography (21-23).

Others have also commented on the negative influence of crossing vessels, although without statistical evidence (24-26). Bogaert et al. (11) report a high success rate of retrograde endopyelotomy in

CURRENT INDICATIONS FOR ENDOPYELOTOMY

Table 1 – Success rate of endopyelotomy according to prognostic factors: vessel crossing UPJ and degree of hydronephrosis (form reference 20). Data presented at the 17th World Congress of Endourology, Rhodes, September 1999

Risk factors	No.	% Success
• Vessel absent and low-grade (1-2) hydronephrosis	41/46	89
• Vessel absent	66/80	82.5
• Low-grade (1-2) hydronephrosis	48/59	81
• Vessel absent and high-grade (3-4) hydronephrosis	25/34	72.5
• High-grade (3-4) hydronephrosis	31/52	60
• Vessel present and low-grade (1-2) hydronephrosis	7/13	54
• Vessel present	13/31	42
• Vessel present and high-grade (3-4) hydronephrosis	6/18	33

children, but state that open surgery remains the standard, particularly when crossing vessels are identified preoperatively; their only failure occurred in a patient with a crossing lower pole vessel. Bagley et al. (27) report a lower success rate when crossing vessels are detected preoperatively by endoluminal ultrasounds (27). In Cohen et al. experience (9), 1/2 unexplained failures after Acucise endopyelotomy occurred in patients with a crossing vessel. Figenshau et al. (28) reported a similar experience with percutaneous endopyelotomy in children. Lim & Walker (29) identified crossing vessels in 2/3 recurrent UPJ obstruction after pyeloplasty in children. At Washington University, Wolf et al. (30) observed that all four patients treated with laparoscopic pyeloplasty after failed endo(uretero)pyelotomy had vessels crossing the ureteropelvic junction. Similar findings were reported by Faerber et al. (10) with Acucise endopyelotomy: 3 of 4 failures re-operated by open pyeloplasty had vessels crossing the UPJ; they therefore recommend to obtain a spiral CT to identify crossing vessels preoperatively and to select another form of therapy when they are present. Although there is no dispute on the influence of crossing vessels on outcome, their relative importance remains a matter of debate. In a series of 401 percutaneous antegrade endopyelotomies, there were 60 failures; 54 were explored and crossing vessels were present in 13 or 24% of cases. The authors concluded that obstructing crossing vessels were potential factors of failure in only 4% of endopyelotomies and that preoperative

identification was not indicated (31). This difference can best be explained by patient selection. Our data are based on the prospective recruitment of every consecutive patient presenting with symptomatic UPJ obstruction during the study period and endoureteropyelotomy was performed regardless of the results of the preoperative work up for crossing vessels. This appears to be the closest one can get to do a randomized study, which is impractical to perform (32). Also in our population more than 80% of patients had a primary type of UPJ obstruction which has a higher likelihood of crossing vessels, whereas in the majority of other series only half of the cases are of congenital origin.

The argument that crossing vessels are present around the UPJ in as many as 71% of kidneys, and that, therefore, they cannot be detrimental to the success of endo(uretero)pyelotomy is not relevant (33,34). Those important and elegant data were obtained from anatomical studies on normal kidneys and clearly demonstrate their vascular anatomy, including their situation in relation to the UPJ, but bear no relation with the actual crossing of the junction in clear cut cases of UPJ obstruction (35). On the contrary, the literature on surgical pyeloplasty is replete with accurate illustrations relevant to UPJ obstruction, and confirms our findings at surgery in case of failed endo(uretero)pyelotomy (36).

The incidence of late failures or recurrences is diversely appreciated. Many authors found that failures occur early, and that late failures or recur-

rences are distinctly uncommon (31,37). A higher incidence of late failures or recurrences was noted in our series (18). Seven of the 18 failures occurred after one year; one even occurred more than 6 years postoperatively. That this might be due to inadequate follow up is unlikely, as all those patients had been followed according to a strict study protocol. As a matter of interest, the 2 patients with the longest time to recurrence (74 and 64 months) have a redundant amount of studies, one being a radiologist's wife (expert in ultrasonography), and the other a urology nurse. In our opinion, corroborated by our operative findings, those cases of late failure are very similar to the well known entity of intermittent hydronephrosis, where a crossing vessel is almost universally present (38); as previously mentioned, in 15 of the 18 failures treated by open pyeloplasty a crossing vessel was found.

These observations do not contradict the fact that long-term success has been achieved in many instances in the presence of crossing vessels. In those instances, we postulate that the operation succeeds in correcting both the intrinsic and the extrinsic factors of obstruction: the functional permeability of the UPJ is reestablished, and also the crossing vessels become somewhat fixed in a silent non-threatening position. In recurrences, we assume that either or both corrections are insufficient, or that the hypotonic renal pelvis is unable to recuperate a minimal function; at the slightest diuretic solicitation the renal pelvis balloons out and protrudes through the vascular window making recurrence inevitable.

The presence of vessels directly crossing the UPJ not only influences the final outcome, but is also a source of potential complications. Vascular complications of endo(uretero)pyelotomy can be significant, and although seldom mentioned and possibly under-reported in the literature, they remain a constant preoccupation to both patient and endourologist (24,39). Because they are rare in some authors' experience, this illustrates their expertise in technique as well as in patient selection (31,37); complications can nevertheless occur and are acknowledged as potentially serious (2). Careful visual inspection of the operative site in order to direct the incision away from pulsating vessels is in-

deed strongly advocated, and is a recognized advantage of endoscopic over blind techniques (37). Reported vascular complications have been summarized in our recent review paper (17); additional reports have been published. Malden et al. (40) described an arteriovenous fistula complicating antegrade endopyelotomy. Brooks et al. (24) needed to transfuse 4/22 (18%) of their endopyelotomy patients. Cohen et al. (9), Stroom et al. (41) and Wagner et al. (42) have each described significant bleeding from direct vascular injury after retrograde endopyelotomy. Cohen et al. (9) acknowledges a 10-15% risk of bleeding from crossing vessels, and suggests that full patient's information is warranted. Gelet et al. (12) reported 2/44 cases of significant bleeding after Acucise endopyelotomy, one originating in an arteriovenous fistula of a crossing vessel. Recent reports confirmed the potential for complex and potentially life-threatening complications after Acucise endopyelotomy: 4% significant bleeding in the report of Kim et al. (43), and 4 vascular lesions in 52 cases (8%) in Schwartz & Stoller's experience (44).

Those data are judged of sufficient importance to justify preoperative documentation of crossing vessels, and the selection of an alternative therapy when they are present (especially when associated with high grade hydronephrosis), at least until one can determine with accuracy which crossing vessels are truly significant, or which renal pelvis will fully recuperate its tone (15,17,23,41,45). Following those guidelines, hemorrhagic complications have all but disappeared and success rate has dramatically increased; Quillin et al. (21) reported the absence of failures in patients without crossing vessels documented by spiral CT. Similarly several authors obtained a success rate of almost 100% in the confirmed absence of crossing vessels (26,46).

The documentation of crossing vessels has the additional benefit to improve postoperative follow up planning, as the risk of long term recurrence increases when crossing vessels are present; moreover, several diagnostic techniques (angiography, spiral CT) reliably detect vessels crossing the contralateral UPJ, which might be advantageous in the follow up of a syndrome that can be bilateral in as many as 10% of cases (20,21).

Degree of Hydronephrosis

By essence endourologic procedures can only address intrinsic factors of obstruction, and extrinsic factors cannot be corrected by a strictly endourologic technique; in addition they cannot reduce the size of a massively distended renal pelvis. From early experience the negative influence of the size of the renal pelvis on the results of endopyelotomy was suspected (3,47). A careful analysis of prognostic factors in our prospective series proved that the degree of hydronephrosis was of statistical significance when combined with the presence or absence of crossing vessels: in the presence of crossing vessels, the risk of failure was more than tripled by high grade versus low grade hydronephrosis; the final success rate was found to drop from 81% to 54% when high grade hydronephrosis was present. In a recent review of 401 percutaneous antegrade endopyelotomies from a single Institution, the overall success rate was 85%; high grade hydronephrosis as well as poor renal function were significant causes of failure: patients with massive hydronephrosis had only a 50% success rate compared to 96% for those with moderate hydronephrosis (31). Unfortunately in this monumental study no correlation with crossing vessels can be drawn as any systematic data have been obtained.

Length of Stricture

Long avascular strictures, total obliteration of the ureteropelvic junction and severe periureteral fibrosis are clear contraindications to endourological procedures; they should be treated by open repair. Although isolated cases may have been successfully managed, global results are in general unsatisfactory (3,25,47-51).

Renal Function

Renal function is a significant prognostic factor. A high risk of failure has been reported when the function of the affected kidney is greatly impaired (30,49,52,53). Unfortunately the isolated impact of this factor is difficult to assess as no prospective data have been collected. In most series preoperative function of the involved kidney has been systematically assessed only recently and in selected cases, and its influence cannot be dissociated from that of the degree of hydronephrosis (30,54).

NON SIGNIFICANT RISK FACTORS

Type of Obstruction:

Primary versus Secondary UPJ Obstruction

Initially, only secondary cases of ureteropelvic junction obstruction were considered ideally suited for endopyelotomy, as the endourological procedure avoided a difficult open reintervention and did not interfere with the delicate periureteral vasculature that could be injured by open dissection. It was later recognized that primary cases of UPJ could also be treated endoscopically, and commendable success rates have been achieved. In most recent series, secondary cases of UPJ obstruction appear to respond slightly better to antegrade endopyelotomy: a cumulated success rate of 84% is achieved, as opposed to 79% for primary type of obstruction (55).

Type of Procedure: Antegrade versus Retrograde Endo(uretero)Pyelotomy

The success rate of endopyelotomy appears to be independent of the type of surgical approach. Results of contemporary series of retrograde endopyelotomy compare favorably with antegrade percutaneous procedures; no difference is noted between procedures performed under direct ureterorenoscopic approach and indirect fluoroscopic control (4,56,57). Although simple dilation of the UPJ does not appear to be sufficient, at least in adults, growing evidence is showing that similar results on secondary UPJ strictures can be obtained with endoballoon rupture as well as with Acucise (1) endopyelotomy (6,8,57-59). Also with antegrade endopyelotomy, the invagination technique and the classical percutaneous technique have similar success rates (12,60,61). Neither does the type of incisional device significantly influence the outcome: similar results are obtained with laser incision, cold and hot knives, semi-lunar or hook knives. The type of stent and the experience of the surgeon (once the operative technique has been mastered) do not influence the outcome (18,31).

Age, Sex and Side of Obstruction

Pediatric experience was slow to accumulate; only limited and selected series are available for review and the procedure is not recommended

in small children (62). Recently however interesting results have been obtained in children older than age 4 with the Acucise balloon, especially in the absence of crossing vessels (11,29). Preliminary experience with smaller children is being reported with encouraging results (11,63,64). In a limited experience, simple balloon dilation appears to be sufficient, and disruption of the UPJ may not be required as it is in adults (65).

The place of endopyelotomy remains controversial in children and open pyeloplasty remains therefore the preferred procedure due to its consistently superior results, especially in primary cases, and to its better tolerance in this age group. In addition most cases are diagnosed very early in life, and surgical correction is recommended at a very early age, where endoscopy remains technically problematic. In secondary cases of UPJ obstruction such as failures of open pyeloplasty, endopyelotomy is however safe and effective and with further refinements and miniaturization of equipment, it may become a preferred option (28,63).

At the other end of the spectrum, in elderly patients, endopyelotomy offers results comparable to the adult group (64,66). Neither the sex of the patient, or the side of the obstruction influences the outcome (1,31).

CURRENT INDICATIONS FOR ENDOPYELOTOMY

Results of endopyelotomy fall somewhat short of contemporary open pyeloplasty (67-95% versus 95-100%). As most endopyelotomy series using different techniques achieve approximately the same results, it appears likely that selection criteria play a major role. Risk factors have been identified: the presence of vessels crossing directly the ureteropelvic junction stands out as a major prognostic factor of outcome; the degree of hydronephrosis, the type of obstruction and renal function also play a role, although of lesser importance (16,55). Long avascular strictures and major alteration of renal function clearly contraindicate the procedure (48).

In our view, the presence of a crossing vessel should be ascertained preoperatively as it signifi-

cantly influences the outcome. Modern diagnostic techniques such as spiral-computed tomography, color Doppler and endoluminal ultrasonography have replaced the more invasive procedures such as angiography (22,23,67). When a significant crossing vessel has been documented, a classical endopyelotomy is likely to provide inadequate results especially in the presence of a large size renal pelvis. When a small artery or a venous channel is encountered, consideration can be given to transection of the crossing vessel (45,55). If a major vessel is present, we would prefer an alternative treatment, such as open or laparoscopic pyeloplasty.

CONCLUSION

With careful attention to operative details, endopyelotomy produces outstanding results with minimal morbidity. The present development of retrograde techniques avoiding the morbidity of a percutaneous access and achieving comparable success are promising.

Prognostic factors such as crossing vessels and high-grade hydronephrosis have been identified. We believe that with better definition of the indications one will further improve the outcome and match open pyeloplasty in well selected patients: in the absence of vessels crossing the UPJ and of massively dilated renal pelvis, a 95% success rate can be expected (20).

REFERENCES

1. Kuenkel M, Korth K: Endopyelotomy: long-term follow-up of 143 patients. *J Endourol*, 4: 109-115, 1990.
2. Badlani G, Karlin G, Smith AD: Complications of endopyelotomy: analysis in a series of 64 patients. *J Urol*, 140: 473-475, 1998.
3. Van Canghai PJ, Jorion JL, Wese FX, Oposomer RJ: Endoureteropyelotomy: percutaneous treatment of ureteropelvic junction obstruction. *J Urol*, 141: 1317-1321, 1989.
4. McClinton S, Steyn JH, Hussey JK: Retrograde balloon dilatation for pelviureteric junction obstruction. *Br J Urol*, 71: 152-155, 1993.

5. Oakley NY, Raza A, Haq AU, Hastie K: Endobrst: simple and safe is best. *J Endourol* 12: 423-428, 1998.
6. Nakada SY, Soble JJ, Gardner SM, Wolf JS Jr, Figenshau RS, Pearle MS, Humphrey PA, Clayman RV: Comparison of Acucise endopyelotomy and endoballoon rupture for management of secondary proximal ureteral stricture in the porcine model. *J Endourol*, 10: 311-318, 1996.
7. Wolf JS: Retrograde Acucise Endopyelotomy. *Urology*, 51: 859-860, 1998.
8. Nadler RB, Rao GS, Pearle MS, Nakada SY, Clayman RV: Acucise endopyelotomy: assessment of long term durability. *J Urol*, 156: 1094-1097, 1996.
9. Cohen TD, Gross MB, Preminger GM: Long-term follow-up of Acucise incision of ureteropelvic junction obstruction and ureteral strictures. *Urology*, 47: 317-323, 1996.
10. Faerber GJ, Richardson TD, farah n, Ohl DA: Retrograde treatment of ureteropelvic junction obstruction using the ureteral cutting balloon catheter. *J Urol*, 157: 454-458, 1997.
11. Bogaert GA, Kogan BA, Mevorach RA, Stoller ML: Efficacy of retrograde endopyelotomy in children. *J Urol*, 156: 734-737, 1996.
12. Gelet A, Combe M, Ramackers JM: Endopyelotomy with the Acucise Cutting balloon: Early clinical experience. *Eur Urol*, 31: 389-393, 1997.
13. Arun N, Kekre NS, Nath V, Gopalakrishnan: Is open pyeloplasty still justified? *Br J Urol*, 80: 379-381, 1997.
14. Renner C, Trede T, Seemann O, Rassweiler J: Laser endopyelotomy: Minimally invasive therapy of ureteropelvic junction stenosis. *J Endourol* 12: 537-544, 1998.
15. Van Cangh PJ: Editorial. Endopyelotomy: a panacea for ureteropelvic junction obstruction? *J Urol*, 159: 66, 1998.
16. Van Cangh PJ, Nesa S: Endopyelotomy: Risk factors and patient selection. *Urol Clin N Amer*, 25: 281-288, 1998.
17. Van Cangh PJ, Nesa S, Galeon M, Tombal B, Wese FX, Dardenne AN, Opsomer R, Lorge F: Vessels around the ureteropelvic junction: significance and imaging by conventional radiology. *J Endourol*, 10: 111-119, 1996.
18. Van Cangh PJ, Wilmart JF, Opsomer RJ, Abi AAD A, Wese FX, Lorge F: Long-term results and late recurrence after endoureteropyelotomy: a critical analysis of prognostic factors. *J Urol*, 151: 934-937, 1994.
19. Van Cangh PJ: Editorial comment: Open surgical exploration after failed endopyelotomy: a 12-year perspective. Gupta M , Tuncay OL, Smith AD. *J Urol*, 157: 1613-1619, 1997.
20. Nesa S, Lorge F, Jamart F, Wese FX, Opsomer RJ, Van Cangh PJ: Long term results after 111 endoureteropyelotomy: a prospective analysis of prognostic factors. *J Endourol*, 13: A26, 1999.
21. Quillin SP, Brink JA, Heiken JP, Siegel CL, McClellan BL, Clayman RV: Helical (spiral) CT angiography for identification of crossing vessels at the ureteropelvic junction. *Am J Roentgenol*, 166: 1125-1130, 1996.
22. Frauscher F, Janetscheck G, Helweg G, Strasser H, Bartsch G, Zur Nedden D: Crossing vessels at the ureteropelvic junction: detection with contrast-enhanced color Doppler imaging. *Radiology* 210: 727-731, 1999.
23. Keely FX, Moussa MA, Miller J, Tolley DA: A prospective study of endoluminal ultrasound versus computerized tomography angiography for detecting crossing vessels at the ureteropelvic junction. *J Urol*, 162: 1938-1941, 1999.
24. Brooks JD, Kavoussi LR, Preminger GM, Scussler WW, Moore RG: Comparison of open and endourologic approaches to the obstructed ureteropelvic junction. *Urology*, 46: 791-795, 1995.
25. Bush WH, Brannen GE, Lewis GP: Ureteropelvic junction obstruction: treatment with percutaneous endopyelotomy. *Radiology*, 171, 535-538, 1989.
26. Ono Y, Hashimoto J, Ohshima S: Percutaneous endoscopic surgery for obstructive disease in the upper urinary tract-preliminary report. *Jap J Urol*, 81: 1247-1251, 1990.
27. Bagley DH, Liu JB, Goldberg BB, Grasso M: Endopyelotomy: importance of crossing vessels

- demonstrated by endoluminal ultrasonography. *J Endourol*, 9: 465-467, 1995.
28. Figenshau RS, Clayman RV, Colberg JW, Coplen DE, Soble JJ, Manley CB: Pediatric endopyelotomy: the Washington University experience. *J Urol*, 156: 2025-2030, 1996.
 29. Lim DJ, Walker RD: Management of the failed pyeloplasty. *J Urol*, 156: 738-740, 1996.
 30. Wolf JS, Siegel CL, Brink JA, Clayman RV: Imaging for ureteropelvic junction obstruction in adults. *J Endourol*, 10: 93-104, 1996.
 31. Gupta M, Tuncay OL, Smith A: Open surgical exploration after failed endopyelotomy: a 12-year experience. *J Urol* 157:1613-1619, 1997.
 32. Cassis A, Brannen GE, Bush WH, Correa RJ, Chambers M: Endopyelotomy: review of results and complications. *J Urol*, 146: 1492-1495, 1991.
 33. Sampaio F: The dilemma of the crossing vessel at the ureteropelvic junction: precise anatomic study. *J Endourol*, 10: 411-415, 1996.
 34. Sampaio FJ, Favorito LA: Ureteropelvic junction stenosis: vascular anatomical background for endopyelotomy. *J Urol*, 150: 1787-1791, 1993.
 35. Sampaio F, Uflacker R: Renal anatomy applied to urology, endourology, and interventional radiology. Thieme Medical Publishers, New York, 1993.
 36. Barnett JS, Stephens FD: The role of the lower segment vessel in the etiology of hydronephrosis. *Aust New Zeal J Surg*, 31: 201-213, 1992.
 37. Motola JA, Badlani GH, Smith AD: Results of 212 consecutive endopyelotomies: an 8-year follow up. *J Urol*, 149: 453-456, 1993.
 38. Hoffer FA, Lebowitz RL: Intermittent hydronephrosis: a unique feature of ureteropelvic junction obstruction caused by a crossing renal vessel. *Radiology*, 156: 655-658, 1985.
 39. Bolton DM, Bogaert GA, Mevorach RA, Kogan BA, Stoller ML: Pediatric ureteropelvic junction obstruction treated with retrograde endopyelotomy. *Urology*, 44: 609-613, 1994.
 40. Malden ES, Picus D, Clayman RV: Arteriovenous fistula complicating endopyelotomy. *J Urol*, 148: 1520-1523, 1992.
 41. Stroom SB, Geisinger MA: Prevention and management of hemorrhage associated with cauterization of ureteropelvic junction obstruction. *J Urol*, 153: 1904-1906, 1995.
 42. Wagner JR, D'Agostino R, Babayan RK: Renal arterioureteral hemorrhage: a complication of Acucise endopyelotomy. *Urology*, 48: 139-141, 1996.
 43. Kim FJ, Herrel SD, Jahoda AE, Albala DM: Complications of Acucise endopyelotomy. *J Endourol* 12: 433-436, 1998.
 44. Schwartz BF, Stoller ML: Complications of retrograde balloon cauterization endopyelotomy. *J Urol*, 162: 1594-1598, 1999.
 45. Keely FX, Bagley DH, Kulp-Hughe D, Gomella LG: Laparoscopic division of crossing vessels at the ureteropelvic junction. *J Endourol*, 10: 163-168, 1996.
 46. Bagley DH, Liu JB, Goldberg B: Endoluminal sonographic imaging of the ureteropelvic junction. *J Endourol* 10: 105-110, 1996.
 47. Brannen GE, Bush WH, Lewis GP: Endopyelotomy for primary repair of ureteropelvic junction obstruction. *J Urol*, 139: 29-32, 1988.
 48. Hulbert JC, Hunter D, Castaneda-Zuniga W: Classification of techniques for the reconstruction of acquired strictures in the region of the ureteropelvic junction. *J Urol*, 140: 468-472, 1988.
 49. Meretyk S, Meretyk I, Kavoussi LR: Ureteronephroscopic vs. Antegrade endopyelotomy for treatment of ureteropelvic junction obstruction. *J Endourol*, 4: S 141, 1990.
 50. Perez LM, Friedman RM, Carson CC: Endoureteropyelotomy in adults. *Urology*, 39: 71-76, 1992.
 51. Preminger GM, Clayman RV, Nakada SY, Babayan RK, Albala DM, Fuchs GJ, Smith AD: A multicenter clinical trial investigating the use of a fluoroscopically controlled cutting balloon catheter for the management of ureteral and ureteropelvic junction obstruction. *J Urol*, 157: 1625-1629, 1997.
 52. Kavoussi LR, Albala DM, Clayman R: Outcome of secondary open surgical procedure in patients who failed primary endopyelotomy. *Br J Urol*, 72: 157-160, 1993.
 53. O'Flynn K, Mc Kelvic G, Steyn J: Endoballoon rupture and stenting for pelvi-ureteric junction

- obstruction technique and early results. *Br J Urol*, 64: 572-574, 1989.
54. Danuser H, Ackermann DK, Bohlen D, Studer UE: Endopyelotomy for primary ureteropelvic junction obstruction: risk factors determine the success rate. *J Urol*, 159: 56-61, 1998.
 55. Van Cangh PJ, Nesa S: Endoureteropyelotomy: *Atlas Urol Clin N Am*, 4: 43-58, 1996.
 56. Thomas R, Monga M, Klein EW: Ureteroscopic retrograde endopyelotomy for management of ureteropelvic junction obstruction. *J Endourol*, 10: 141-145, 1996.
 57. Meretyk I, Meretyk S, Clayman RV: Endopyelotomy: comparison of ureteroscopic retrograde and antegrade percutaneous techniques. *J Urol*, 148: 775-783, 1992.
 58. Tan HL, Roberts JP, Grattan-Smith D: Retrograde balloon dilatation of ureteropelvic obstruction in infants and children: early results. *Urology*, 46: 89-91, 1995.
 59. Kadir S, White RI, Engel R: Balloon dilatation of a ureteropelvic junction obstruction. *Radiology*; 143: 263-264, 1982.
 60. Combe M, Gelet A, Abdelrahim AF, Lopez JG, Dawahra M, Martin X, Marechal JM, Dubernard JM: Ureteropelvic invagination procedure for endopyelotomy (Gelet technique): Results of 51 consecutive cases. *J Endourol*, 10: 153-157, 1996.
 61. Cuzin B, Abbar M, Dawahra M, Viguier JL, Martin X, Gelet A: 100 endopyélotomies percutanées. Techniques, indication, résultats. *Prog Urol*, 2: 559-569, 1992.
 62. Rodrigues Netto N Jr, Ikari O, Esteves SC, D'Ancona CA: Antegrade endopyelotomy for pelviureteric junction obstruction in children. *Br J Urol*, 78: 607-612, 1996.
 63. Kavoussi LR, Meretyk S, Dierks SM, Bigg SW, Gup DI, Manley CB, Shapiro E, Clayman RV: Endopyelotomy for secondary ureteropelvic junction obstruction in children. *J Urol*, 145: 345-349, 1991.
 64. Kletscher BA, Qian J, Bostwick DG, Andrews PE, Zincke H: Percutaneous antegrade endoscopic pyelotomy: review of 50 consecutive cases. *J Urol*, 153: 701-704, 1995.
 65. Tan HL, NajmaLdin A, Webb DR: Endopyelotomy for pelvi-ureteric junction obstruction in children. *Eur Urol*, 24: 84-88, 1993.
 66. Horgan JD, Maidenbergh MJ, Smith AD: Endopyelotomy in the elderly. *J Urol*, 150: 1107-1109, 1993.
 67. Nakada SY, Wolf JS, Brink JA, Quillen SP, Nadler RB, Gaines MV, Clayman RV: Retrospective analysis of the effect of crossing vessels on successful retrograde endopyelotomy outcomes using spiral computerized tomography angiography. *J Urol*, 159: 62-65, 1998.
 68. Van Cangh PJ: The increase in minimally invasive endourology: a tribute to excellence and a plea for thoughtful restraint. Editorial. *J Urol*, 156: 1411, 1996.

Received: December 3, 1999
Accepted: December 10, 1999

Correspondence address:

Paul J. Van Cangh, M.D.
Department of Urology
Catholic University of Louvain Medical School
Cliniques Universitaires St Luc
10, Avenue Hippocrate
B - 1200 Brussels, Belgium
Fax: (0021) 32 2 764-8919
E-mail: vancangh@chex.ucl.ac.be

ADDENDUM

ATLAS OF TECHNICAL CONSIDERATIONS ON ENDOPYELOTOMY MODALITIES
(From Reference 55)

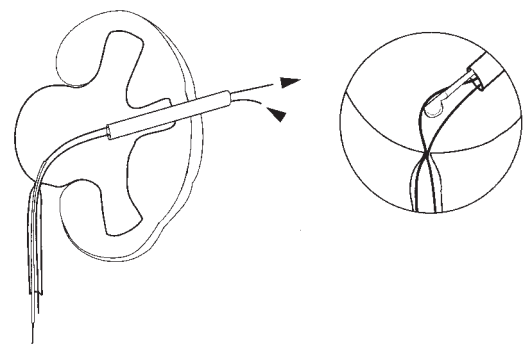


Figure-1: ANTEGRADE PERCUTANEOUS ENDOPYELOTOMY: CLASSICAL TECHNIQUE
In this technique, the UPJ is incised under direct vision until the peripelvic fat is clearly visible. A second guide wire is advantageous to straighten and stiffen the tissues: the cutting knife is literally railroaded on the track (3).

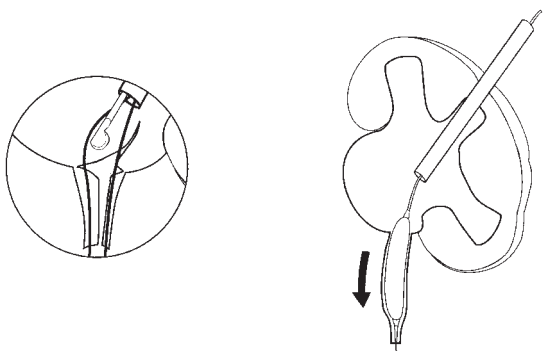


Figure-2: ANTEGRADE PERCUTANEOUS ENDOPYELOTOMY: INVAGINATION TECHNIQUE
A dilation balloon is inflated below the UPJ and attracted inside the renal pelvis by traction on the exteriorized guide wire, thereby invaginating the UPJ and the proximal ureter. The double layer of the renal pelvis and ureter is incised using an electrocautery and a small electrode (60). This technique facilitates the incision as the tissue is stabilized on the dilated balloon; it may also reduce the risk of damaging crossing vessels, although such complications have occurred (61).

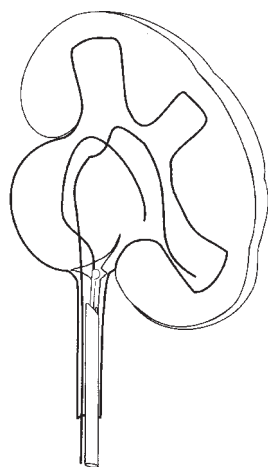


Figure-3: RETROGRADE URETEROSCOPIC ENDOPYELOTOMY
A small caliber ureterorenoscope is advanced up to the level of the UPJ and a postero-lateral incision is performed under direct vision. A preliminary insertion of a double-J stent remaining in-situ for two weeks greatly facilitates this maneuver, but adds to the complexity of the procedure, which remains technically difficult, especially in male patients (56).

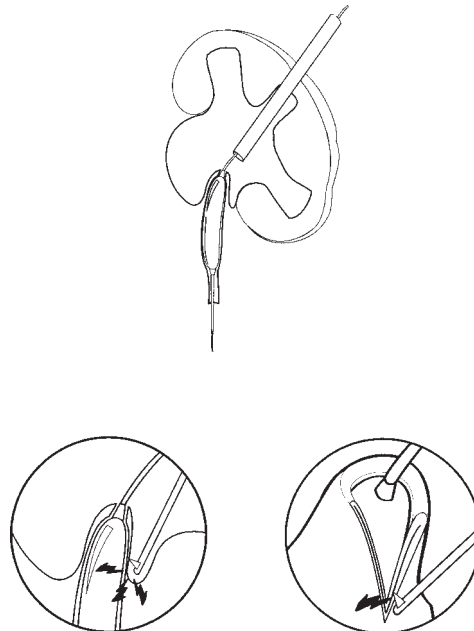

Figure-4: ACUCISE ENDOPYELOTOMY
The device consists of a low-pressure balloon fitted with an electrocautery wire active over the 2-cm expandable portion of the balloon. The UPJ is not forcibly disrupted, but cleanly cut by the wire that is activated during inflation of the balloon positioned across the UPJ (51).