

MAGNETIC RESONANCE IN DIAGNOSIS OF URETEROCELE

HUMBERTO DO NASCIMENTO, MAURÍCIO HACHUL, ANTÔNIO MACEDO JR

Division of Urology, Federal University of São Paulo, UNIFESP, São Paulo, SP, Brazil

ABSTRACT

Ultrasonography is the main non-invasive technique for screening of ureterocele, but presents some difficulties for its diagnosis. Other supplementary diagnostic methods have the disadvantage of being invasive or using ionizing radiation. Magnetic resonance (MR) has a high sensitivity for diagnosing urinary tract malformations in adults and children. We report one case of ureterocele in a 1-year old child with the purpose of presenting its diagnosis through MR

Key words: ureter; infant; ureterocele; diagnosis; magnetic resonance
Int Braz J Urol. 2003; 29: 248-250

INTRODUCTION

The study of urinary tract anatomy and pathology in pediatric patients can be obtained by a number of imaging methods. Ultrasonography represents the main screening technique, but rarely it enables an accurate analysis of the entire urinary tract. Other diagnostic methods such as voiding urethrocytography, excretory urography, computerized tomography, ascending pyelography, cystoscopy and renal scintigraphy complement the diagnosis, but have the disadvantage of exposing the patient to invasive procedures or to ionizing radiation. Uro-resonance has a high sensibility for the diagnosis of urinary tract malformations in adults and children (1), and can be performed by 2 distinct techniques: one that uses images of the body's static fluids (the technique employed in this case) and the other using a paramagnetic contrast medium associated with a diuretic. The technique that employs paramagnetic contrast and diuretic, do not require the dilatation of the excretory system, presenting a better contrast in image and a higher sensitivity.

CASE REPORT

We studied a female, 1-year old patient, with a clinical history of recurrent urinary tract infection since birth. Ultrasonography evidenced severe bilateral pyelocaliceal dilatation and left pyelocaliceal duplication, with an image inside the bladder suggesting ureterocele. Voiding urethrocytography demonstrated absence of vesicoureteral reflux, excretory urography showed functional exclusion of the right kidney, and scintigraphy with DMSA showed 9% of function on the right side. The diagnosis of left ureterocele was confirmed by uro-resonance (Figure-1). An endoscopic puncture of the ureterocele was performed without interurrences and the child evolved with clearing of the ipsilateral renal unit.

COMMENTS

Ultrasonography is a good examination for viewing pyelocaliceal duplicity; however, it is limited for a complete study of the ureter. In the dilated urinary tract, the ureterovesical junction can be eas-

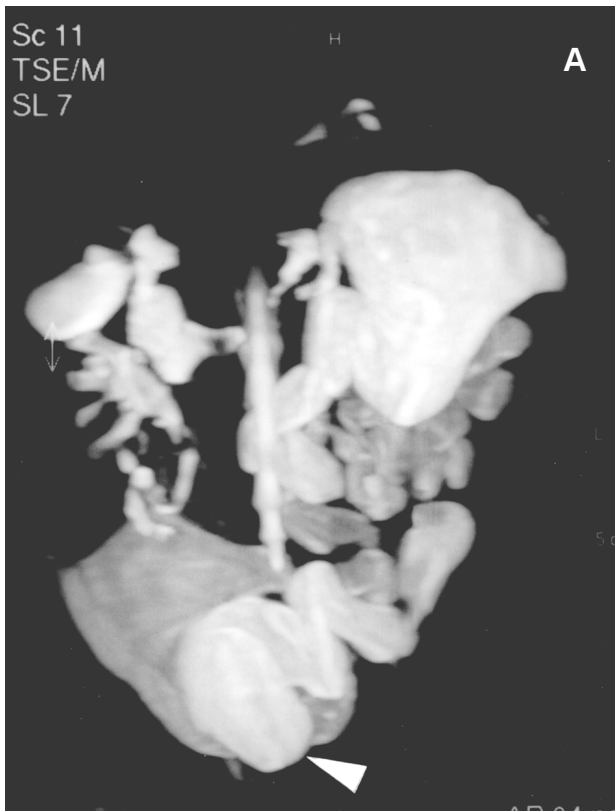

Figure 1 A – Weighted image in T2, in frontal plane, showing pyeloureteral duplication and ureterocele (arrow).

ily localized by ultrasound, but it is impaired in ectopic or slightly dilated ureters. Computerized tomography can be employed as an alternative diagnostic technical modality; however, the exposure to high doses of radiation restricts its use in pediatrics (2).

Uro-resonance can be employed in cases of dilated ureters and functional exclusion, because it provides an adequate visualization of the entire urinary tract. It defines the morphology and the thickness of the renal parenchyma, and additionally it provides an indirect analysis of renal function concerning urinary excretion. It is a rapid technique, which contributes substantially to the diagnosis of ureterocele, since its performance does not depend on the patient's respiratory rate and offers images with high definition and quality.

Recently, the utilization of uro-resonance in the prenatal diagnosis of ureterocele has significantly




Figure 1 B – Weighted image in T2, in frontal plane. The illustrative arrow shows a rounded image with regular contours, in the interior of bladder, corresponding to ureterocele.

decreased morbidity, potential lesions due to repeated urinary infections, and the need of secondary surgical interventions (3). Magnetic resonance can be an alternative in relation to conventional diagnostic techniques, since it does not expose the patient to ionizing radiation or the use of an iodinated intravenous contrast medium.

Uro-resonance images are acquired in weighted sequences in T2, in frontal (coronal) or sagittal sections, presenting very prolonged echo time and repetition time, promoting an adequate analysis of the urinary tract's morphology. Uro-resonance weighted in T2 can be performed with administration of furosemide before the examination, but the identification of urinary tract can be impaired if those are not dilated. Adding a paramagnetic contrast medium (gadolinium), favors the adequate study of kidneys and urinary tract, even in the absence of dilatation, promoting a more sensitive and more specific diagnosis.

REFERENCES

1. Borthne A, Pierre-Jerome C, Nordshus T, Reiser T: MR urography in children: current status and future development. *Eur Radiol.* 2002; 10: 503-11.

2. Staatz G, Rohrmann D: Magnetic resonance urography in children: evaluation of suspected ureteral ectopia in duplex systems. *J Urol.* 2002; 166: 2346-50.
3. Upadhyay J, Bolduc S, Braga L, Farhat W, Bagli DF, McLorie GA, et al: Impact of prenatal diagnosis on the morbidity associated with ureterocele management. *J Urol.* 2002; 167: 2560-5.

Received: January 8, 2003

Accepted after revision: May 6, 2003

Correspondence address:

Dr. Humberto do Nascimento
Disciplina de Urologia, UNIFESP
Rua Napoleão de Barros, 715 – 2º andar
São Paulo, SP, 04024-002, Brazil
E-mail: humbertojr1@aol.com