

## COMPARISON OF LAPAROSCOPIC LIVE DONOR NEPHRECTOMY VERSUS THE TRADITIONAL OPEN TECHNIQUE

TIBÉRIO M. SIQUEIRA JR., RYAN F. PATERSON, RAMSAY L. KUO, LARRY H. STEVENS,  
JAMES E. LINGEMAN, ARIEH L. SHALHAV

*Department of Urology, Indiana University School of Medicine, Methodist Hospital Institute for Kidney Stone Disease, and Department of General Surgery, Methodist Hospital of Indiana, Clarian Health Partners, Indianapolis, Indiana, USA*

### ABSTRACT

**Objectives:** Laparoscopic live donor nephrectomy (LDN) is a minimally invasive technique for kidney procurement that may decrease the donor disincentives. In addition, recent studies have demonstrated that LDN has equal graft and recipient survival when compared to the standard open approach. We report our experience with LDN and compare the results with the most recent open donor nephrectomy (ODN) group performed at our institutions.

**Material and Methods:** The records of 70 consecutive left sided LDN performed between October 1998 and March 2001 were retrospectively reviewed and compared to 40 ODN performed between April 1996 and January 2000.

**Results:** Average blood loss (127 ml vs. 317 ml;  $p < 0.001$ ), time to PO intake (25 hrs vs. 34.6 hrs;  $p < 0.001$ ), and hospital stay (2.7 d vs. 4.2 d;  $p < 0.001$ ) were statistically significant better for the LDN group when compared to ODN group. The average warm ischemia time in the LDN group was 138 seconds (range 55 - 360). The major complication rate in both laparoscopic (4 cases) and open (2 cases) donor groups was similar (5.7% and 5%, respectively). The average post-operative day (POD) 90 recipient creatinine was similar for both groups ( $1.5 \pm 0.9$  vs.  $1.5 \pm 0.8$  ng/dL;  $p = 0.799$ ). Similar rates of recipient ureteral complications occurred in the LDN and ODN groups: 1.4% (1 case) and 2.5% (1 case), respectively. Likewise, acute rejection was also similar at 22.8% (16 cases) and 27.5% (11 cases) in the LDN and ODN respectively.

**Conclusions:** At our institutions, LDN was superior to ODN with regards to donor operative blood loss, time to PO intake, and length of hospital stay. In addition, similar complication rates, and 3-month recipient kidney function were demonstrated.

**Key words:** kidney; transplantation; laparoscopy; nephrectomy

**Int Braz J Urol. 2002; 28: 394-402**

## INTRODUCTION

Renal transplantation remains the only chance for end-stage renal disease patients to be free of dialysis. Live renal transplantation shows potential advantages when compared to cadaveric donor renal transplantation: longer patient and graft survival, shorter time on the renal transplant wait list, optimal conditions for allograft retrieval, improved HLA matching, shorter cold ischemic time and decreased immunosuppression regimens (1,2). Despite these po-

tential advantages, only a third of all renal transplantations performed in United States involve live donors (3).

Laparoscopic nephrectomy was initially described as an alternative to open surgery for the treatment of benign renal disease (4). The similar results achieved with this technique when compared to the open approach for the same procedure, encouraged a broadening of the indications to other urologic procedures (5-7). In 1995, Ratner et al. (8) described the first laparoscopic live donor nephrectomy (LDN) and,

since then, many centers around the country have been using this technique for living renal transplantations. This minimally invasive technique for kidney procurement potentially decreases the donor disincentives (9,10), and multiple studies have demonstrated equal graft and recipient survival when compared to the standard open approach (11-16). Schweitzer et al. (17) noted an increase in the willingness of potential donors to undergo the donation in their institution. Similarly, Ratner et al. (18) observed an increase of 25% in live kidney donations due to the laparoscopic approach in donors who would not have donated if the open surgery was the only option. Herein, we report our experience with LDN and compare the results with the most recent open live donor nephrectomy (ODN) group performed at our institutions.

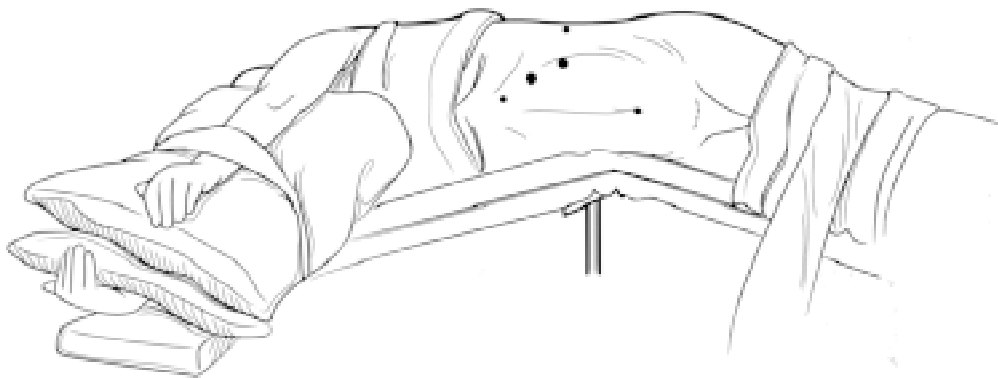
## MATERIALS AND METHODS

The records of 70 consecutive left sided LDN performed between October 1998 and March 2001

were retrospectively reviewed and compared to 40 ODN performed between April 1996 and January 2000.

## Perioperative Care

Helical three-dimensional computerized angio-tomography was performed in all donors to evaluate the vascular and collecting system anatomy. For both groups, the donors received clear liquids and magnesium citrate bowel preparation the day before surgery. A second-generation cephalosporin was administered 1 hour before skin incision. Sequential compression devices were placed in order to prevent embolism, and a nasogastric tube and a Foley catheter were inserted in all donor patients. The nasogastric tube was removed at the end of surgery, and the Foley catheter was removed on the morning of post-operative day one. Intra-operatively, all patients received 2-3L of crystalloids in order to maintain a good urinary output (2 cc/kg/h). Before renal pedicle clamping, 12.5 g of mannitol were administered.



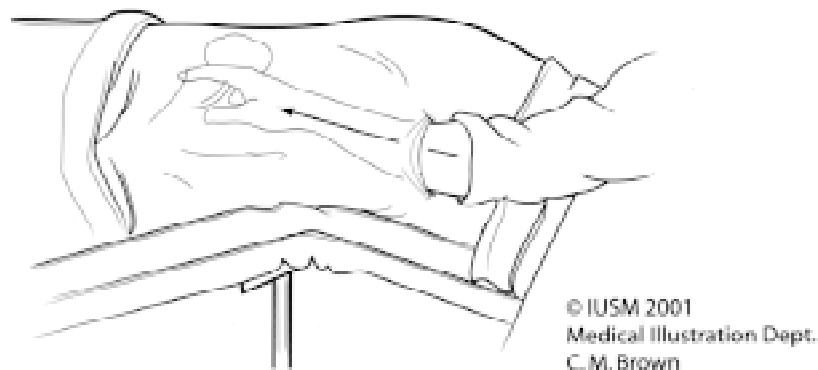
© IUSM 2001  
Medical Illustration Dept.  
C. M. Brown

**Figure 1 - Ports configuration:** Two 12mm trocars are placed (large dots). The first one approximately 8cm below the rib cage, at the lateral border of the rectus muscle, the other port, approximately 8cm below the rib cage at the anterior axillary line. Three additional 5mm trocars are placed (small dots): the first one approximately 5cm below the rib cage at the border of the lateral rectus muscle; the second just inferior to the umbilicus, and the last port in the mid axillary line about 5cm below the rib cage, after the colon had been reflected medially.

### Laparoscopic Live Donor Nephrectomy Group

The patients were placed in a right sided flank position, with the upper body rotated posteriorly about 30 degrees, and kidney rest elevated. Right-sided kidneys were not used because of the high risk of renal vein thrombosis after recipient implantation (12). A 5-port configuration was used in all 70 patients (Figure-1). The initial trocar was placed approximately 8cm below the rib cage at the lateral border of the rectus muscle. Peritoneal cavity entry was achieved at this site using the Optiview 12mm blunt-tipped trocar (19) (Ethicon Endo-Surgery, Cincinnati, OH), and a pneumoperitoneum of 14 mm Hg achieved. Under direct vision, a second 12mm blunt-tipped trocar was placed at the anterior axillary line, approximately 8cm below the rib cage. Three additional 5 mm ports were then placed: a)- The first one approximately 4 cm below the rib cage at the lateral border of the rectus muscle; b)- The second just inferior to the umbilicus; c)- The last port in the mid-axillary line approximately 5 cm below the rib cage, after the colon had been reflected medially. The 5mm harmonic scalpel (*Ethicon Endo-Surgery*, Cincinnati, OH) was used in all cases for active dissection and coagulation of small vessels, reserving the bipolar electrocautery for larger bleeding points. Adrenal and gonadal veins were dissected circumferentially, clipped, and incised. The renal vein was then circumferentially dissected free until

it could be retracted superiorly, exposing the neuro-lymphatic tissue covering the renal artery. Dissection then continued through the neuro-lymphatic tissue until the renal artery was completely dissected to its origin from the aorta. Care was taken to keep intact the perinephric fat close to the renal hilum, to prevent any injury to the vessels feeding the ureter. The ureter was dissected inferiorly to the crossing of the iliac artery, clipped and divided. Once the kidney was only attached by the renal pedicle, the artery and vein were divided sequentially using the endo-GIA stapler (Auto Suture, Norwalk, CT) through the lateral 12mm port. The kidney was removed using an EndoCatch bag (Auto Suture, Norwalk, CT) through a sub-umbilical midline incision in the first 43 cases, or manually through a modified Pfannenstiel incision in the last 27 cases (20) (Figure-2). Prior to stapling, anticoagulation was achieved with the administration of 100 units/kg of heparin intravenously and reversed with 1 mg/kg of protamine intravenously after pedicle division. Hemostasis was assured under direct vision after the pneumoperitoneum pressure was reduced to 4 mm of Hg. The rectus muscles fascia (site of kidney removal) was then closed using a running No. 1 PDS suture. Trocars were removed under direct vision and no fascial closure was performed at the trocar sites. The skin incisions were closed using subcuticular 4-0 monocryl.



**Figure 2** - Specimen retrieval. Note the assistant's right hand lifting the kidney. After renal vessels division, the kidney is manually removed from the abdomen through a modified Pfannenstiel incision.

**Table 1 - Donor demographics.**

	Laparoscopic	Open
Number	70 patients	40 patients
Age (years)	39.1 (19-61)	38 (23-59)
Male: Female	28:42	18:22
Body Mass Index	23.33 (22.36-34.13)	29.27 (22.08-41.53)

The procured kidneys were flushed with Euro-Collins solution and kept in ice slush preparation before recipient implantation.

### Open Live Donor Nephrectomy Group

Procured kidneys were removed through an extraperitoneal flank or transabdominal subcostal incision, depending on the transplantation team preference. After removal, the kidneys were flushed with Euro-Collins solution and kept in ice slush preparation before recipient implantation.

### Recipients

The procured kidneys were implanted through a standard extraperitoneal Gibson incision in all recipients. End-to-side vascular anastomosis between renal vessels and external iliac vessels, as well as an extravesical ureteroneocystostomy (Lich-Gregoir technique) were performed in all recipients. Antithymocyte globulin induction with steroids, mycophenolate mofetil, and delayed Tacrolimus (after kidney function was well established) were used in the recipients as immunosuppression regimen.

Statistical analysis was performed using the Student *t* test, and the data was expressed as the mean plus or minus one standard deviation.

**Table 2 - Peri-operative donor data.**

	Laparoscopic	Open	p Value
Warm ischemia time (sec)	138 (55-360)	Not recorded	
Estimated blood loss (ml)	127 ± 142	317 ± 214	< 0.001
Time to ambulate (hrs)	24.8 ± 9.6	30.4 ± 13.5	0.128
PO intake (hrs)	25.0 ± 10.1	34.6 ± 14.8	< 0.001
Highest post-op creatinine (ng/dL)	1.3 ± 0.3	1.4 ± 0.3	0.876
Hospital stay (days)	2.7 ± 0.9	4.2 ± 2.5	< 0.001

### RESULTS

Donor demographics are shown in Table-1 and peri-operative donor data is shown in Table-2. Mean operative time was 164min (80-300) and 190min (100-280), in the LDN and ODN group, respectively. Estimated blood loss (127 mL vs. 317 ml;  $p < 0.001$ ), time to PO intake (25hrs vs. 34.6hrs;  $p < 0.001$ ), and mean hospital stay (2.7d vs. 4.2 d;  $p < 0.001$ ) were also significantly less in the LDN group. Warm ischemia time (WIT) was 138 seconds (range 55-360) in laparoscopic group. No WIT was recorded in the open group.

A total of 11 complications (15%) occurred in the LDN group (Table-3). Of these, 4 were major (5.7%), with bleeding representing 2 cases. The first complication was related to a segmental renal vein injury caused by the Kitner retractor, while the second case was caused when a right angle clip slipped off from a short adrenal vein stump. Two units of blood were transfused in the first patient. Open conversion was performed in both cases. The third major complication was an inadvertent upper ureter transection during the lower pole dissection. The procedure was completed laparoscopically, and an end-to-side uretero-ureterostomy between the ureter of the transplanted kid-

**Table 3 - Laparoscopic and open donor complications.**

	<b>Laparoscopic (15%)</b>		<b>Open (7.5%)</b>
Major	Venous bleeding	(n = 2)	Lumbar vein injury (n = 2)
	Ureteral injury	(n = 1)	
	Splenic injury	(n = 1)	
Minor	Atelectasis	(n = 1)	Incisional hernia (n = 1)
	Duodenal ulcer	(n = 1)	
	Respiratory distress	(n = 1)	
	Scrotal swelling	(n = 1)	
	Thigh numbness	(n = 1)	
	Testicular pain	(n = 1)	
	Atrial fibrillation	(n = 1)	

ney and the native right ureter was performed in the recipient. The kidney showed immediate function after implantation, and the stent was removed at 6 weeks. No ureteral extravasation or stricture has been observed after 22 months of follow-up. The last major complication in the LDN group was a splenic injury caused by the metal rim of the EndoCatch device (Auto Suture, Norwalk, CT) used to retrieve the kidney. Following cauterization of the splenic laceration and apparent hemostasis at a pneumoperitoneum pressure of 4 mm Hg, the patient was sent to the recovery room in stable condition. On POD 1, the patient presented with hypotension and an acute drop in hemoglobin. Three units of blood were transfused, but the patient continued to display signs of hemodynamic instability, and was taken back for an exploratory laparotomy. Active bleeding was seen coming from the spleen, and the decision was to perform a splenectomy. The patient had an uneventful post-operative course and recovery.

The open group showed 1 minor and 2 major complications (7.5%) (Table-3). Bleeding during renal pedicle dissection was responsible for both

major complications. No transfusions were needed.

No significant difference in recipient renal function was noted between LDN and ODN groups (Table-4).

A similar rate of complications in recipients of LDN and ODN kidneys was encountered (Table-5). One case of ureteral obstruction occurred in the laparoscopic group (1.4%), which was attributed to a blood clot. During reoperation, no sign of ischemia or extravasation from the distal ureter was observed. The patient underwent ureteral reimplantation with good outcome. Similarly, one ureteral complication occurred in the open group (2.5%). The patient presented with a peritransplant urine collection on POD 1. Surgical exploration revealed a partial uretero-vesical anastomotic disruption. After ureteral reimplantation, the patient had an uneventful recovery. Sixteen patients (22.8%) in the laparoscopic and 11 patients (27.5%) in the open group presented with varying degrees of acute rejection. One recipient in the open group returned to dialysis on POD 16 due to arterial thrombosis, and one recipient in the LDN

**Table 4 - Creatinine evolution in both recipient groups.**

	<b>Laparoscopic</b>	<b>Open</b>	<b>p Value</b>
Creatinine: POD 1	2.9 ± 1.6	3.5 ± 1.8	0.038
Creatinine: POD 4	1.6 ± 1.4	1.8 ± 1.8	0.567
Creatinine: POD30	1.4 ± 0.6	1.8 ± 1.6	0.151
Creatinine: POD 90	1.5 ± 0.9	1.5 ± 0.8	0.799

group returned to dialyses due to acute rejection. One recipient in the LDN group died on POD 15 due to cryptococcal meningitis.

## DISCUSSION

Live donor nephrectomy is a unique operation as it exposes an otherwise healthy person to potentially major complications for another person's benefit. This procedure has been performed through an open approach for several decades (1,2). However, encouraging results with the laparoscopic treatment of urologic diseases, prompted Ratner et al. (8) to perform the first human LDN in 1995. Since then, multiple authors have reported good results with this approach (11-16). In order to be accepted as a substitute for the traditional open approach, LDN has to fulfill several criteria. First, donors submitted to laparoscopic nephrectomy should not be exposed to additional morbidity when compared to the open donors. In addition, procured kidneys should have overall graft survival and renal function rates similar to those kidneys harvested by the open approach. Finally, the laparoscopic approach must offer advantages to the donor such as diminished post-operative pain, improved cosmesis, shorter hospital stay and earlier return to normal activities (11-16).

Others have compared the results obtained with the laparoscopic and open approach, reporting equivalent recipient outcomes and significant reductions in donor morbidity (11-16). Our series is additional evidence that LDN is becoming a standard of care. In our patients, estimated blood loss, resumption of PO intake, and hospital stay, were significantly lower in the LDN group. Moreover, although the use of postoperative analgesic was not assessed, the decreased time to ambulate after surgery, associated with the use of a small infra-umbilical or a Pfannenstiel incision to retrieve the procured kidney and, the shorter hospital stay, showed that the laparoscopic approach is less painful than the open approach.

Historically, the overall incidence of complications for the traditional open approach ranges between 8 to 47% (21). There were 11 complications (15%) observed in the LDN group, similar to the rate in open series. In addition, only 4 of these were major

(5.7%), which showed no difference when compared to the ODN group (5%). The 2 bleeding complications in the LDN group could be avoidable. Currently, instead of using laparoscopic clips to control the left renal vein branches, we are coagulating these vessels with the bipolar electrocautery, and dividing them with the harmonic scalpel. Since this modification was introduced, no complications related to clip dislodgement have been observed. Furthermore, the lack of clips at the renal vein tributaries, have facilitated the positioning of the endo-GIA to safely divide the renal vessels. The inadvertent upper ureter division and the splenic injury were observed early in this series, and were attributed to the learning curve. As stated before, in the last 27 cases, the procured kidney was manually removed through a modified Pfannenstiel incision instead of using the EndoCatch bag. This modification allowed us to have a more controlled setting during the endo-GIA positioning and firing across the renal vessels, preventing potential complications. Additionally, using the manual retrieval, WIT was lowered from 173 to 101 seconds ( $p < 0.001$ ) (20).

The incidence of recipient ureteral ischemic complications for LDN ranges between 2% to 11.2%. Generally, these complications tend to occur early in the series, and are associated to the use of monopolar cautery to dissect the ureter (9,11,13,15,18). The use of harmonic scalpel has been reported to result in significantly reduced lateral tissue damage when compared to the monopolar electrocautery (22,23). In this series, the harmonic scalpel was used for dissection and coagulation in all cases. To date, no recipient ureteral strictures in the initial 126 LDN have been observed.

Delayed graft function after renal transplantation is generally associated with prolonged warm ischemia time and, consequently, acute tubular necrosis (15). In addition, during LDN, the renal vein compression caused by the pneumoperitoneum can lead to diminished renal plasma flow and oliguria, which could potentially increase the risk of acute tubular necrosis (24,25). This series and previous reports did not observe this effect on the laparoscopically harvested transplanted kidneys (11,12). In fact, all transplanted kidneys in the LDN group functioned immediately after recipient implan-

tation. Despite this, 16 patients (22.8%) in the LDN group developed some degree of acute rejection, but only one case returned to dialysis due to sustained rejection. The incidence of acute rejection in the open group was similar to the laparoscopic group.

Although the LDN series represents our learning curve, we were able to achieve recipient and donor results similar to those achieved with the established open approach, associated with reduced donor morbidity. The authors believe that in a near future, the laparoscopic approach will become the standard of care to procure kidneys in live donor renal transplantation.

## CONCLUSIONS

At our institutions, laparoscopic live donor nephrectomy showed similar short-term recipient results as those achieved with the open approach. Laparoscopic donor patients demonstrated a significant decrease in average blood loss, resumption of postoperative oral intake and mean hospital stay, when compared to the open group. The complication rate was similar to that in the ODN group. This series provides additional data for the growing body of evidence that LDN is becoming a standard of care for living renal transplantation.

---

*Ms. Tracy Robinson and Ms. Stephanie Derdak compiled the laparoscopic renal transplant database, Ms. Naomi Fineberg performed the statistical analysis. The Endourological Society and the Boston Scientific Corporation supported in part this work.*

## REFERENCES

- Dunn JF, Nylander WA, Richie RE, Johnson HK, MacDonnell RC, Sawyers JL: Living related kidney donors: A 14 year experience. *Ann Surg.* 1996; 203: 637-42.
- Waples MJ, Belzer FO, Uehling DT: Living donor nephrectomy: A 20 year experience. *Urology.* 1995; 45: 207-10.
- Annual Report of the US Scientific Registry of Transplant recipients and the Organ Procurement and Transplantation Network. Transplant data, 1988-1997. United Network for Organ Sharing (UNOS), 1996. Rockville, Maryland: United States Department of Health and Human Services, 1998.
- Clayman RV, Kavoussi LR, Soper NJ, Dierks SN, Meretyk S, Darcy MD, et al.: Laparoscopic nephrectomy: initial case report. *J Urol.* 1991; 146: 278-82.
- Kavoussi LR, Kerbl K, Capelouto CC, McDougall EM, Clayman RV: Laparoscopic nephrectomy for renal neoplasms. *Urology.* 1993; 42: 603-9.
- Shalhav AL, Portis AJ, McDougall EM, Patel M, Clayman RV: Laparoscopic nephroureterectomy. A new standard for the surgical management of upper tract transitional cell cancer. *Urol Clin North Am.* 2000; 27: 761-73.
- Gill IS: Laparoscopic radical nephrectomy for cancer. *Urol Clin North Am.* 2000; 27: 707-19.
- Ratner LE, Ciseck LJ, Moore RG, Cigarroa FG, Kaufman HS, Kavoussi LR: Laparoscopic live donor nephrectomy. *Transplantation.* 1995; 15: 1047-9.
- Jacobs SC, Cho E, Dunkin BJ, Flowers JL, Schweitzer E, Cangro C, et al.: Laparoscopic live donor nephrectomy: the University of Maryland 3-year experience. *J Uro.* 2000; 164: 1494-9.
- Ratner LE, Hiller J, Sroka M, Weber R, Sikorsky I, Montgomery RA, et al.: Laparoscopic live donor nephrectomy removes disincentives to live donation. *Transplant Proc.* 1997; 29: 3402-3.
- Brown ST, Biehl TR, Rawlins MC, Hefty TR: Laparoscopic live donor nephrectomy: A comparison with the conventional open approach. *J Urol.* 2001; 165: 766-9.
- Lee BR, Chow GK, Ratner LE, Kavoussi LR: Laparoscopic live donor nephrectomy: Outcomes equivalent to open surgery. *J Endourol.* 2000; 14: 811-20.
- Philosophe B, Kuo PC, Schweitzer EJ, Farney AC, Lim JW, Johnson LB, et al.: Laparoscopic versus open donor nephrectomy: Comparing ureteral complications in the recipients and improving the laparoscopic technique. *Transplantation* 1999; 68: 497-502.
- Ratner LE, Kavoussi LR, Schulam PG, Bender JS, Magnuson TH, Montgomery R: Comparison of laparoscopic live donor nephrectomy versus the standard open approach. *Transplant Proc.* 1997; 29: 138-9.
- Flowers JL, Jacobs S, Cho E, Morton A, Rosenberger WF, Evans D, et al.: Comparison of open and laparoscopic live donor nephrectomy. *Ann Surg.* 1997; 226: 483-90.
- Hawasli A, Boutt A, Cousins G, Schervish E, Oh H:

- Laparoscopic versus conventional live donor nephrectomy: Experience in a community transplant program. *Amer Surg.* 2001; 67: 342-5.
17. Schweitzer EJ, Wilson J, Jacobs S, Machan CH, Philosophe B, Farney A, et al.: Increased rates of donation with laparoscopic donor nephrectomy. *Ann Surg.* 2000; 232: 392-400.
  18. Ratner LE, Montgomery RA, Kavoussi LR: Laparoscopic live donor nephrectomy: the four year Johns Hopkins University experience. *Nephrol Dial Transplant.* 1999; 14: 2090-3.
  19. Wolf JS, Jr.: Laparoscopic access with a visualizing trocar. *Tech Urol.* 1997; 3: 34-7.
  20. Shalhav AL, Siqueira TM, Jr., Gardner TA, Paterson RF, Stevens LH: Manual specimen retrieval without a pneumoperitoneum preserving device for laparoscopic live donor nephrectomy. *J Urol* (submitted for review), 2002.
  21. Fabrizio MD, Ratner LE, Kavoussi LR: Laparoscopic live donor nephrectomy: pro. *Urology* 1999; 53: 665-7.
  22. Lamm P, Juchem G, Weyrich P, Schutz A, Reichart B: The harmonic scalpel: optimizing the quality of mammary artery bypass grafts. *Ann Thorac Surg.* 2000, 69: 1833-5.
  23. Inaba H, Kaneko Y, Ohtsuka T, Ezure M, Tanaka K, Ueno K, et al.: Minimal damage during endoscopic latissimus dorsi muscle mobilization with the harmonic scalpel. *Ann Thorac Surg.* 2000; 69: 1399-401.
  24. McDougall EM, Monk TG, Wolf JS, Jr., Hicks M, Clayman RV, Gardner S, et al.: The effect of prolonged pneumoperitoneum on renal function in an animal model. *Am Coll Surg.* 1996; 182: 317-28.
  25. Kirsch AJ, Hensle TW, Chang DT, Kayton ML, Olsson CA, Sawczuk IS: Renal effects of CO<sub>2</sub> insufflation: Oliguria and acute renal dysfunction in a rat pneumoperitoneum model. *Urology* 1994; 43: 453-9.

---

*Received: April 12, 2002*

*Accepted: June 28, 2002*

---

**Correspondence address:**

Dr. Arie L. Shalhav  
 535 N. Barnhill Dr, Suite 420  
 Indianapolis, Indiana, 46202, USA  
 Fax: + 1 317 274-0174  
 E-mail: ashalhav@iupui.edu

**EDITORIAL COMMENT**

The authors are to be congratulated for this study in which they present their series of 70 laparoscopic live donor nephrectomies. The surgical outcome of this series adds to multiple studies already published in the literature, and confirms that the laparoscopic approach provides excellent surgical outcomes, comparable to the open surgical approach with significant advantages in terms of blood loss, parenteral analgesic usage, hospital stay, convalescence, and superior cosmesis.

However, we take issue with the author's excluding right donor nephrectomies due to a "high

risk of renal vein thrombosis after recipient implantation". An established principle of kidney transplantation is to preserve the better kidney with the donor. As such, right donor nephrectomy has been performed in up to 35% of patients in some open series(1). Right-sided live donor nephrectomy is indicated in the setting of multiple left renal arteries or anatomically compromised kidney. Anatomically, the right renal vein is significantly shorter compared to the left renal vein, increasing the technical challenge of right donor nephrectomy. We employ the retroperitoneoscopic approach for the right-sided donor nephrectomy, which

provides excellent exposure of the right renal vein directly as it joins the vena cava. This allows complete harvesting of the right renal vein by placing the EndoGIA stapler (U.S. Surgical, Norwalk, CT) flush with the vena cava (2).

We reviewed retrospectively 90 patients undergoing laparoscopic donor nephrectomy at our institute from October 1997 to August 2001 (3). Right retroperitoneoscopic donor nephrectomy was performed in 25 patients (28%). Mean right renal vein length was 1.5cm. Operative time was 3 hours, and warm ischemia time was 5min. The kidney was extracted from a muscle splitting extraperitoneal Gibson incision and hospital stay was 2.2 days. No kidneys were lost, and recipient mean serum creatinine was 1.9 and 1.27, at 5 and 30 days post transplant, respectively. In conclusion, right laparoscopic donor nephrectomy is safe and results in donor and recipient outcomes are comparable to left laparoscopic donor ne-

phrectomy. Although the length of the right renal vein was clearly shorter, it did not compromise the transplantation procedure.

#### References

1. Barry, JM: Editorial comment. *J Urol*, 164: 1499, 2000.
2. Gill IS, Uzzo RG, Hobart MG, Strem SB, Goldfarb DA, Noble MJ: Laparoscopic retroperitoneal live donor nephrectomy for purposes of allotransplantation and autotransplantation. *J Urol*. 2000; 164: 1500-4.
3. Ng CS, Abou El-Fettouh HI, Goldfarb DA, Gill IS. Retroperitoneal versus transperitoneal laparoscopic live donor nephrectomy. *J Urol*. 2002; 167 (suppl.): 383 (Abst #1524).

**Dr. Jihad H. Kaouk**  
**Dr. Inderbir S. Gill**

*Section of Laparoscopic and Minimally Invasive Surgery  
Urologic Institute, The Cleveland Clinic Foundation  
Cleveland, Ohio, USA*

#### REPLY BY AUTHORS

We congratulate the reviewers for the large and positive experience with right laparoscopic donor nephrectomy (LDN).

However comparing their result for right LDN with our results for left LDN, the warm ischemia time was 50% shorter (average 2 min 28 sec vs. 5 min) and the early recipient creatinine was better (average 1.6 on post operative day 4 vs. 1.9 on post operative day 5) for the left LDN.

The long term significance of these differences is yet to be established. Also the reviewers do not report their complication rate related to right sided LDN.

We have performed 5 right sided LDN, the average warm ischemia time was 3 min 10 sec and 2 of these kidneys showed early acute tubular necrosis (ATN) that resolved after 5 and 7 days. Average creatinine of these 5 patients was 1.7 at 30 days. Based on our experience, we recommend that the left kidney be preferably used for LDN, especially during the initial 50 cases of LDN, and only then attempt right sided LDN.

The principle of leaving the donor with the best kidney should be kept, but in proportion. The sensitivity of computerized tomography is such that it detects asymptomatic small renal stones and renal cysts that were previously not detected by intravenous pyelogram and angiogram. The larger than 30 years experience with kidney donors preoperatively assessed by these modalities teaches us that these abnormalities did not result in renal function compromise for any of the donors. As such at Indiana university the criteria for potential left LDN include those donors older than 40 years, asymptomatic, with a right renal stone up to 5mm and up to 2 renal cysts up to 1cm. At Indiana University 7 such patients had left LDN and are now asymptomatic on appropriate follow-up.

**Dr. Arieh L. Shalhav**

*Associate Professor of Surgery  
Director of Minimally Invasive Urology  
The University of Chicago  
Chicago, Illinois, USA*