

PRIAPISM – ETIOLOGY, PATHOPHYSIOLOGY AND MANAGEMENT

C. VAN DER HORST, HENRIK STUEBINGER, CHRISTOPH SEIF, DIETHILD MELCHIOR,
F.J. MARTÍNEZ-PORTILLO, K.P. JUENEMANN

Department of Urology, University Hospital Schleswig Holstein, Campus Kiel, Germany

ABSTRACT

The understanding of erectile physiology has improved the prompt diagnosis and treatment of priapism. Priapism is defined as prolonged and persistent erection of the penis without sexual stimulation and failure to subside despite orgasm. Numerous etiologies of this condition are considered. Among others a disturbed detumescence mechanism, which may be due to excess release of contractile neurotransmitters, obstruction of draining venules, malfunction of the intrinsic detumescence mechanism or prolonged relaxation of intracavernosal smooth muscle are postulated. Treatment of priapism varies from a conservative medical to a drastic surgical approach. Two main types of priapism; veno-occlusive low flow (ischemic) and arterial high flow (non-ischemic), must be distinguished to choose the correct treatment option for each type. Patient history, physical examination, penile hemodynamics and corporeal metabolic blood quality provides distinction between a static or dynamic pathology. Priapism can be treated effectively with intracavernous vasoconstrictive agents or surgical shunting. Alternative options, such as intracavernous injection of methylene blue (MB) or selective penile arterial embolization (SPEA), for the management of high and low flow priapism are described and a survey on current treatment modalities is given.

Key words: priapism; classification; pathophysiology; etiology; treatment; pharmacologic therapy; surgery

Int Braz J Urol. 2003; 29: 391-400

INTRODUCTION

Definition

Priapism is a persisting erection caused by disturbances in the mechanism controlling penile detumescence and the maintenance of penile flaccidity. However, priapism will either start *de novo*, as a result of a prolonged nocturnal erection, or may persist after sexual intercourse. During priapism, blood continues to accumulate in the cavernous sinusoids and, in time, results in painful erection. The corpora cavernosa become rigid and painful, whereas the corpus spongiosum and the glans penis remain soft and uninvolved.

Medically, priapism is defined as persisting, painful and abnormal tumescence that can occur without any sexual stimulation and which does not subside after sexual intercourse or masturbation (1). Furthermore priapism is caused by disturbances in the mechanism controlling penile detumescence and the maintenance of penile flaccidity due to excess release of contractile neurotransmitter, malfunction of the intrinsic detumescence mechanism, obstruction of draining venules or prolonged relaxation of intracavernous smooth muscle. This condition frequently results in erectile failure and is considered as a urologic emergency (1,2). Prolonged corporeal ischemia lasting more than 24 to 48 hours may result in varying extents of irreversible fibrosis with endot-

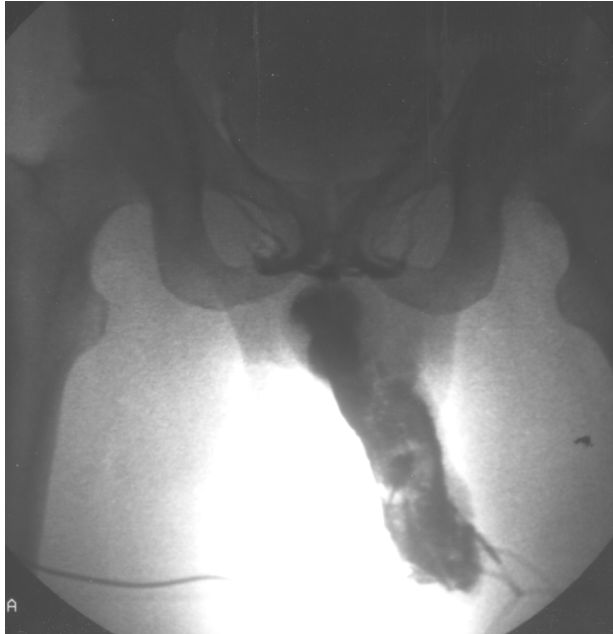

Figure 1 – Corporeal cavernosography demonstrating irreversible fibrosis of the cavernosal tissue after an episode of painful priapism lasting more than 48 hours.

helial and trabecula destruction of the erectile tissue and subsequently in permanent erectile dysfunction (2) (Figure-1). After 48h widespread smooth muscle necrosis will take place (3). The natural sequelae of untreated ischemic priapism is penile fibrosis and impotence (4). On their long-term follow-up (mean 66 months) El-Bahnasawy and co-workers reported only a 43% rate of preserved erectile function after a long lasting priapism (median range of duration 48h) (5).

Erectile dysfunction is the most outstanding late complication. The incidence of this latter is directly related to the duration of priapism and necessarily used aggressive treatment methods. As a result of priapism the overall rate of erectile dysfunction can be as high as 59%. High-flow arterial priapism shows a lower incidence of erectile dysfunction up to 20% (6). To preserve erectile function immediate urological consultation must be provided.

The duration time of a normal erection before it is classifiable as priapism is still controversial. Ongoing penile erections for more than 6 hours can be classified as priapism owing to studies analyzing blood gases revealing ischemia and acidosis after 4 to 6 hours that could lead to potential damage (7,8).

Physiology of Penile Erection

Penile erection is a complex neurovascular event involving the interaction of three physiological systems: the central nervous system (CNS), the peripheral nervous system and the penile arterial and trabecula smooth muscle (9). The penile corpora, a specialized vascular tissue, consisting of endothelial-lined sinusoidal spaces supported by a framework of smooth muscle, collagen, nerves, nutritive arterioles and capillaries (4). Normal erectile function is a complex interaction of both, the nervous and vascular system. Erection requires relaxation of trabecula smooth muscle that results in an increased compliance of the sinusoids and arterial wall as well as a dilatation of the arterioles and arteries. As a result of arterial engorgement that occurs through smooth muscle dilatation, a three step mechanism providing full erection follows. Expanding sinusoids are sampling blood passively. Resulting in compression of the subtunical venous plexuses sited into the trabecula network between the tunica albuginea and the peripheral sinusoids. This reduces venous outflow. Stretching of the tunica albuginea to its capacity enclosing the emissary veins between the tunica layers leading to a decreased venous outflow (4). The smooth muscle relaxation during erection depends upon the promotion of Ca^{2+} efflux. This relaxation of smooth muscle cells is mediated mainly by nitric oxide, which activates the enzyme guanylate cyclase. This cytoplasmic enzyme increases formation of the second messenger, cGMP. Elevated levels of peripheral cGMP in turn promote the efflux of Ca^{2+} ions from the cavernosa smooth muscle cells. This induces muscle relaxation, facilitates blood flow into the corpora cavernosa, and thereby helps to obtain and maintain penile erection (10) (see also Figure-2). Under physiological conditions the process of penile detumescence, mediated by efferent sympathetic pathways, follows the tumescence phase. Adrenergic sympathetic nerves release norepinephrine, which acts on adrenoceptors in penile smooth muscle. This result in reduced arterial inflow diminished lacunar space volume and accelerated corporeal venous outflow (11,12). The flaccid state of the penis is maintained by contraction of penile smooth muscle cells medi-

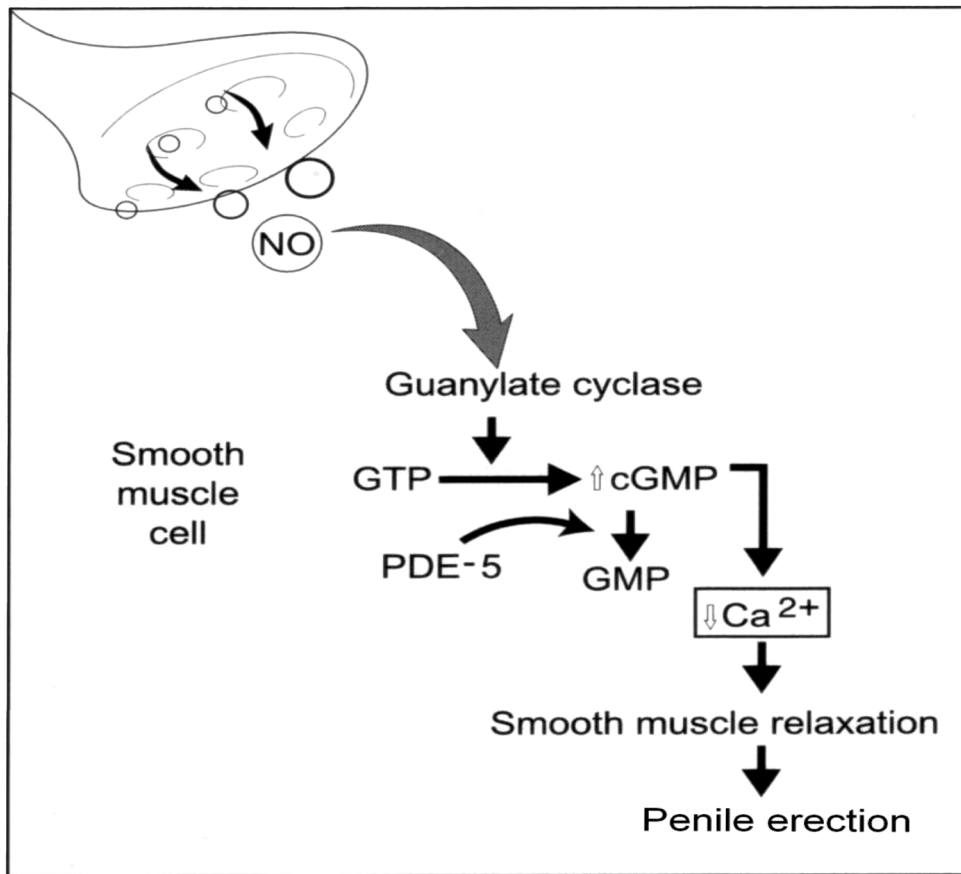


Figure 2 – Cavernosal smooth muscle relaxation during erection depends on nitric oxide resulting in a Ca^{2+} efflux. This induces muscle relaxation, facilitates blood flow into the corpora cavernosa, obtaining and maintaining penile erection.

ated by the intracellular accumulation of Ca^{2+} ions, which is mainly effected by noradrenergic stimulation of α_1 -adrenergic receptors (9,13).

Despite the fact that the metabolic rate of corporal smooth muscles has not been reported yet, the penis as an external organ supplies a decreased temperature compared to the mean warmth of the central body. Therefore its energy requirements can be met at very low blood flow rates. During sexual excitement, the helicine arteries dilate and straighten which in turn allows blood to enter directly into the sinusoidal spaces. At that time, there is a 5-10 fold increase in blood flow to the penis. Intracavernosal needle aspiration of blood during normal erection has a pO_2 of approximately 40 mmHg, a pCO_2 of 40 mmHg and a pH of 7.4 (4,14).

ETIOLOGY AND PATHOPHYSIOLOGY

Over the last years, improved comprehension of the physiology and pharmacology of erectile function has led to a wider knowledge on etiology, pathophysiology and treatment of priapism (15-17). As a result, the treatment of priapism has evolved from predominantly surgical management to less invasive pharmacological therapies (18). For this reason, it is important to distinguish between arterial and veno-occlusive priapism as the choice of treatment depends on the underlying pathophysiology. Meanwhile, the diagnosis and therapeutically management of arterial priapism still remains controversial (19), whereas the diagnosis and treatment of veno-occlusive priapism has become well established.

The cause of priapism can be primary, secondary or idiopathic. Priapism with primary etiology is not accompanied by a disorder responsible for a prolonged erection, e.g. of physical or psychological origin (20). Secondary priapism is induced by factors directly or indirectly affecting the penile erection (Table-1). It has been suggested that the increasing frequency of priapism is related to the rising widespread use of intracavernous injection therapy (CCIT) for erectile dysfunction (2). Between 1.1% (for PGE1) and 7.7% (combination of papaverine and phentolamine) of patients treated with CCIT develop a prolonged erection (21). The cause of an idiopathic priapism cannot be traced and no pathological conditions are obvious. Its incidence is estimated between 50% and 60% (4,6,15,22).

During initial assessment, depending from the underlying hemodynamic pathology, the physician must distinguish between the 2 basic types of priapism – high flow (non-ischemic) and low flow (ischemic) – as the methods of treatment and prognosis differ accordingly (1,4,14,23). The etiology of arterial high-flow priapism remains unclear, although pharmacological, traumatic and neurological diseases have been proposed (24,25). High-flow priapism results from unregulated, continuous arterial inflow into the lacunar spaces (an arterial-lacunar fistula), usually secondary to a lacerated cavernosal artery from blunt or penetrating trauma (25). The increase arterial flow is not regulated by helicine arteries and does not activate the veno-occlusive mechanism (4). The paucity of cases reported in the literature implies that arterial priapism is a rare urological disorder (6,26). Initially CCIT induced high-flow priapism as an increase in arterial flow is evident. With time the veno-occlusive mechanism becomes activated changing into a painful, ischemic low-flow priapism (15).

The more common low-flow or veno-occlusive priapism results from persistent obstruction of venous outflow from the lacunar spaces (27). 80% to 90% of clinically presented priapisms are low flow disorders (6,15).

In order to specify the type of priapism precisely, the assessment of history, physical examination, penile hemodynamics and corporeal metabolic blood quality (Tables-2 and 3) is essential. In ischemic

low flow priapism, venous outflow is not revealed by cavernosonography and pulsation is not palpable. One of the main pathologies of low flow priapism is blood stasis in the corpora cavernosa resulting in low pO_2 and high pCO_2 . The pH of corporeal blood drops below 7.0 (acidosis). Erection then becomes painful and irreversible corporeal fibrosis can develop (Figure-1). Pain is associated with tissue hypoxia and acidosis. Urgent therapeutic intervention with irrigation and corporeal blood aspiration of up to 150 ml to 200 ml is necessary.

In color-flow duplex sonography, the often painless, non-ischemic high-flow priapism shows a high arterial inflow and cavernosonography reveals normal venous outflow. The pH rises above 7.0. The blood gas level is similar to that of arterial blood. Color-flow duplex sonography was proposed to be a less invasive diagnostic examination method as opposed to cavernosonography (15,19).

CONSERVATIVE TREATMENT FOR PRIAPISM

Pharmacological-mediated priapism possibly has increased with the widespread administration of invasive intracavernous substances in the treatment of erectile dysfunction. At present, various therapeutically options exist: mechanical (sustained perineal compression and ice packs), pharmacological (intracavernous, venous or oral drug administration), radiological (selective transcatheter embolization therapy) and surgical (arterial ligation or arteriovenous shunts) (26). Less invasive procedures are more and more successful in numerous cases and the need for surgical intervention decreases. Prevailing disorders such as severe atherosclerotic vascular disease, hypertension, hematological disease and other disturbances contraindicate or render ineffective one or more of these therapeutically options (20,28). Conservative management should be first-choice treatment to avoid erectile dysfunction, especially after shunt procedures (20). However, a stepwise approach to priapism has been recommended, starting with corporeal aspiration of blood and irrigation with non-heparinized saline as a first line therapy. Especially in low flow priapism, it is important to treat the pa-

Table 1 – Etiologies of priapism

Hematologic	Traumatic and Surgical	Neoplastic	Neurologic	Infective toxic allergy	Pharmacologic
- sickle cell disease	- spinal cord injury	- primary sarcoma	- herniated disc (lumbar)	- prostatitis	- papaverine
- leukemia	- penile trauma	- metastasis	- ruptured cerebral aneurysm	- urethritis	- theophylline
- thalassemia	- perineal trauma	- myeloma	- spinal cord tumor or metastasis	- phimosis	- prostaglandin E
- polycythemia	- pelvic trauma	- prostate cancer	- multiple sclerosis	- mumps	- nitroglycerine
- thrombocytasthenia	- arterial anastomosis to corpus	- penis cancer	- spinal tumor with compression	- syphilis	- verapamil
- coagulopathologies	- scorpion and snake venom	- lymphoma	- spinal anesthesia	- malaria	- imipramine
- hemophilia		- bladder carcinoma	- cycling	- rabies	- haloperidol
- corpus cavernosal thrombosis		- paraneoplastic		- diabetes mellitus	- phenelzine
- congenital dyserythropoietic anemia		- urethral carcinoma		- atypical pneumonia	- cannabis
				- acute appendicitis	- doxozosine
					- cocaine
					- clozapine
					- prazosine
					- trazodone
					- vancomycine
					- quetiapine
					- chlorpromazine
					- heparin
					- alcohol
					- erythropoietin

Table 2 – Metabolic and hemodynamic classification of priapism (intracavernosal ASTRUP)

	High-flow	Low-flow
p ^{O2}	> 60 kPa	<< 60 kPa
p ^{CO2}	< 70 kPa	>> 70 kPa
p ^H	> 7.0	< 7.0
Pain	—	++
Pulsation	++	—
Palpation	Elastic	Sturdy
Arterial inflow	High	Low
Venous outflow	Open	Closed
Viscosity	Low	High

tient expeditiously by increasing the outflow of cavernous blood. This procedure is followed by intracavernous injection of vasoconstrictive agents and finally progressing to surgical procedures designed to shunt blood from the corpora cavernosa to the corpus spongiosum or to the vena saphena (22,24,29).

Pharmacological intervention comprises intracavernous injection of metamadol or alpha-adrenergic agonists such as phenylephrine, norepinephrine, ethylephrine and epinephrine – all with similar

Table 3 – Oral and intracorporeal agents for the therapy of priapism

Intracavernous Application	
Drug	Dose
Epinephrine	0.03 – 0.05 mg
Etylephrine	2 - 20 mg
Phenylephrine	0.1 - 1 mg
Norepinephrine	0.01 – 0.02 mg
Methylene blue	50 mg
Intravenous / oral application	
Drug	Dose
Dopamine	2 - 4 µg / kg i.v.
Terbutaline sulfate	5 mg oral
Ketamine hydrochloride	1 mg / kg i.v. or i.m.

modes of action – and oral or intravenous administration of sympathomimetics such as dopamine or terbutaline (12,16,20,30,31) (Table-3). Alpha-agonist agents exert a vasoconstrictive effect on smooth muscle. Intracavernous injection of these drugs can cause pain, hematoma, infection and fibrosis of the penis (20). In order to avoid systemic complications, it is of outstanding importance to inject the agent into the fully erected corporeal cavernosa only (32). As no blood is retained in the penis, local administration of these agents may lead to such systemic complications as sustained hypertension up to 200 mmHg or cerebral bleeding (26,33).

Alpha-agonists for oral administration may be taken into consideration, but hypertension and cardiac arrhythmia could assert a limiting effect (20). This report considered the successful oral use of terbutaline (2.5 to 5 mg), a β_2 -adrenergic-agonist, for recurrent idiopathic priapism. In 5 patients the priapism resolved completely within 30 minutes after oral administration of 5 mg terbutaline. β_2 -agonists should be used with caution in patients with severe arterial coronary disease, suspected excessive intravascular fluid volume or low potassium because this latter can cause tachycardia and pulmonary edema.

Looking for other safe, effective and non-invasive surgical or radiological treatment options with minimal systemic side effects, investigations with methylene blue (MB) have been carried out by various groups (18,34,35). This agent counteracts corpus cavernosa smooth muscle relaxation and vasodilatation, thus enabling penile detumescence. It is well known that neural-mediated vasodilatation and cavernous smooth muscle relaxation produce tumescence (16). Nitric oxide (NO) released from parasympathetic nerve endings activates a guanylate cyclase that leads to elevation of cGMP (36). GTP or ATP is converted to its cyclic monophosphate components, which is thought to produce a fall in cytosolic calcium causing the relaxation of smooth muscle. The use of MB is justified by its ability to inhibit guanylate cyclase and thereby block smooth muscle relaxation initiated by nitric oxide (NO) or other agents that cause a rise in cGMP (18,34,36,37) (Figure-2). Furthermore, MB finds wide topical and intravenous administration in clinical practice. It has virtually no significant side

effects and is rapidly excreted by the kidneys into the urine. The routine use of intracavernous MB in the treatment of priapism is appealing, since its toxicity and systemic side effects could prove slighter than those of commonly used alpha-adrenergic agents (18). Whilst treating 11 patients for priapism, deHoll et al. aspirated up to 200 ml corporeal blood and then intracavernosal injection of 50 mg MB for a 3 to 5 minutes period (34). The MB was then also aspirated and the penis was lightly compressed for 5 minutes. Immediate detumescence was the response in 67% of these patients. There was a 100% response in patients suffering priapism after intracavernous injection therapy (prostaglandin E1). Alpha-agonists offered no benefit in cases where MB was unsuccessful. These results confirmed that MB is effective in the treatment of pharmacologically-induced priapism. A temporary blue discoloration of the penis was noted subsequent to treatment with this substance. Further to this, after injection of MB, patients complained of a burning sensation in the penis that fortunately subsided within a short time (35). Despite this, penile necrosis has been observed after intracavernous administration of MB. Necrosis was attributed to cavernous fibrosis in one patient with a history of 5 years intermittent priapism and after performing an ineffective shunt surgery (38). In our opinion, MB alone provides favorable results if the existing endothelium is in good condition (35). With respect to these observations and in accordance to Mejean et al. (38) we do not recommend the administration of MB in cases of suspected corporeal fibrosis, e.g. in patients with a long history of recurrent priapism. Fibrosis possibly inhibits the endothelial action of MB and thus eventually eliminates any positive effect (38). It is therefore of eminent importance to aspirate the injected MB. In consequence, to exclude any possible existence of fibrosis, MB should only be administered during the first hours of priapism. No cutaneous necrosis was observed at the injection site in our patient cohort.

The sickle cell mediated priapism is normally treated with pharmacotherapy. The main step of therapy is hydration, alkalization, analgesia and hemodilution, which is used to increase the hemoglobin concentration. If conservative measures are inef-

fective, then the former described therapy options must be attempted (4). Gonadotropin-releasing hormone (GnRH) analogues have been tried for the chronic treatment of recurrent priapism. Antiandrogens like flutamide can be administered as well (27).

INVASIVE TREATMENT FOR PRIAPISM

Despite widespread administration of pharmacological substances in the treatment of priapism, there is still a call for surgical intervention if all attempts of conservative treatment fail. A wide range of surgical procedures is established for this type of treatment. This includes proximal ligation of the internal pudendal artery, anastomosis between the corpus cavernosum and the saphenous vein (Grayhack et al. shunt) see Figure-3 (39), cavernous spongiosum shunt (Winter shunt), see Figure-4 (22), cavernosal dorsal vein shunt, incision, irrigation and drainage of corporeal sinuses, percutaneous aspiration of the corpus cavernosum, division of the pudendal nerves and ischiocavernosum muscle, amputation of the penis if associated with malignant disease of the genitalia, and other procedures (20).

The Winter shunt is the most common procedure (22). With this technique, a fistula is created between the glans penis and the corpora cavernosa. The success rate of these procedures ranges between 50% and 65% (40). Possible postoperative complications are infection of the corpora cavernosa with abscess formation, urethral injury leading to stricture or urethrocutaneous fistula and penile hematoma with or without penile thrombosis resulting in erectile dysfunction (6).

The problem with these surgical procedures is the high rate of erectile dysfunction (50%). Therefore they should only be used after failed conservative treatment (29). If erectile dysfunction is present the best treatment is implantation of a penile prosthesis to enable the patient to sexual intercourse (41).

The recurrence of painful priapism despite treatment with pharmacological agents and surgical shunting procedures must be taken seriously. Reported failure rates for surgical treatment up to 50% short-term efficacy and minimal morbidity prompted



Figure 3 – Grayhack-shunt (saphenacavernous shunt)

Bastuba et al. to evaluate the use of selective penile arterial embolization (SPAE) (26). Candidates for SPAE underwent diagnostic arteriography of the pelvis with bilateral selective injections of the internal pudendal arteries that revealed a unilateral arterial-lacunar fistula in all cases first. A catheter was advanced up to the level of the ipsilateral common penile artery. Approximately 3 ml autologous clot were either unilaterally or bilaterally injected until complete stasis was achieved, producing a transient interruption of arterial flow. This resulted in immediate pain relief with subsequent detumescence in all the patients treated by SPAE. Post-embolization arteriogram studies documented the occlusion of the cavernous artery. Normal erectile function, with a delay of up to 5 months because of clot lysis, was restored in 86% of the patients. This group of investigators propagated SPAE as a successful treatment option for high-flow priapism attributed to trauma or A-V fistulas. Potential complications after emboliza-

tion include penile gangrene, persistent erectile dysfunction, gluteal ischemia, perineal abscess or migration of embolization material (4,18).

CONCLUSIONS

Priapism is a considered urologic emergency and should be treated prompt and consequent. The treatment options for all types of priapism are initially conservative but surgical therapy must be available when applicable. MB is an effective and safe treatment for priapism. This approach is most suitable for drug-mediated high-flow priapism (corpus cavernosum injection therapy, CCIT) of short duration. Alpha-agonists offered no benefit in cases where MB was unsuccessful. Apparently, either MB or alpha-agonists can be initially administered. However, if one of these substances fails to take effect, no additional benefit is likely to be gained from the other. When mechanical compression and pharmacological

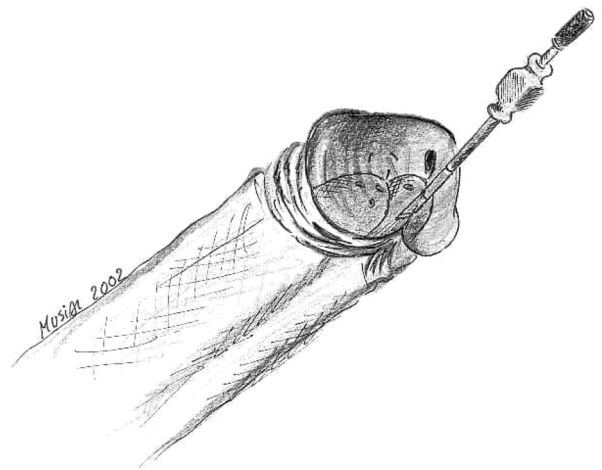


Figure 4 – Winter-shunt (percutaneous glandulocavernous shunt with a True-Cut-Needle)

treatment after the aspiration of cavernous blood do not take effect, then the alternatives are either a surgical shunt procedure or selective arterial embolization. Embolization is a less invasive option for refractory priapism. The restoration of erectile function with MB treatment and unilateral common penile arterial embolization is possible.

REFERENCES

- Hauri D, Spycher M, Bruhlmann W: Erection and priapism - a new pathophysiological concept. *Urol Int.* 1983; 88: 138-45.
- Hashmat AI, Rehman JU: Priapism. In: Hashmat AI, Das S (eds.), *The Penis*. Philadelphia, Lea & Febiger. 1993; pp 219-43.
- Spycher MA, Hauri D: The ultrastructure of the erectile tissue in priapism. *J Urol.* 1986; 135: 142-7.
- Melman A, Serels S: Priapism. *Int J Imp Res.* 2000; 12 (Suppl 4): 133-9.
- El-Bahnasawy MS, Dawood A, Farouk A: Low-flow priapism: risk factors for erectile dysfunction. *BJU Int.* 2002; 89: 285-90.
- Parivar F, Lue TF: Priapism. In: Hellstrom WJG (ed.), *Male Infertility and Sexual Dysfunction*. Berlin, Springer-Verlag. 1997; 401-8.
- Broderick GA, Gordon D, Hypolite J, Levin RM: Anoxia and corporeal smooth muscle dysfunction: a model for ischemic priapism. *J Urol.* 1994; 151: 259-62.
- Juenemann KP, Lue TF, Abozeid M, Hellstrom WJG, Tanagho EA: Blood gas analysis in drug induced penile erections. *Urol Int.* 1986; 41: 207-11.
- Wagner G, Mulhall J: Pathophysiology and diagnosis of male erectile dysfunction. *Int J Imp Res.* 2001; 88 (Suppl 3): 3-10.
- Burnett AL: Role of nitric oxide in the physiology of erection. *Biol Reprod.* 1995; 52: 485-9.
- Diederichs W, Stief CG, Lue TF, Tanagho EA: Norepinephrine involvement in penile detumescence. *J Urol.* 1990; 143: 1264-6.
- Koga S, Shiraiishi K, Saito Y: Post-traumatic priapism treated with metaraminol bitartrate: case report. *J Trauma.* 1990; 30: 1591-3.
- Chuang AT, Steers WD: Neurophysiology of Penile Erection. In Carson CC, Kirby RS, Goldstein I (eds.), *Textbook of Erectile Dysfunction*. Oxford, ISIS Medical Media. 1999; pp 59-72.
- Martínez Portillo FJ, Juenemann KP: New aspects in the treatment of priapism. *Andrologia.* 1999; 31 (Suppl): 53-8.
- Juenemann KP: Priapismus. In: Thüroff JW (ed.), *Urologische Differentialdiagnose*. Stuttgart, Georg Thieme Verlag. 1995; pp 301-8.
- Lue TF, Tanagho EA: Physiology of erection and pharmacological management of impotence. *J Urol.* 1987; 137: 829-36.
- Pohl J, Pott B, Kleinhans G: Priapism - A three-phase concept of management according to etiology and prognosis. *Br J Urol.* 1986; 58: 113-8.
- Steers WD, Selby JB: Use of methylene blue and selective embolization of the pudendal artery for high flow priapism refractory to medical and surgical treatment. *J Urol.* 1991; 146: 1361-3.
- Brock G, Breza J, Lue TF, Tanagho EA: High flow priapism: a spectrum of disease. *J Urol.* 1993; 150: 968-71.
- Shanta TR, Finnerty DP, Rodriguez AP: Treatment of persistent penile erection and priapism using terbutaline. *J Urol.* 1989; 141: 1427-9.
- Spahn M, Manning M, Juenemann KP: Intracavernosal Therapy. In: Carson CC, Kirby RS, Goldstein I (eds.), *Textbook of Erectile Dysfunction*. Oxford, ISIS Medical Media. 1999; pp 345-53.
- Winter CC: Priapism treated by modification of creation of fistulas between glans penis and corpora cavernosa. *J Urol.* 1979; 121: 743-4.
- Hormon WJ, Nehra A: Priapism. In: Hashmat AI, Das S (eds.) *The Penis*. Philadelphia, Lea & Febiger. 1997; pp 219-43.
- Lue TF, Hellstrom WJG, McAninch JW, Tanagho EA: Priapism: a refined approach to diagnosis and treatment. *J Urol.* 1986; 136: 104-8.
- Witt MA, Goldstein I, Saenz de Tejada I, Greenfield A, Krane RJ: Traumatic laceration of intracavernosal arteries: the pathophysiology of non-ischemic, high flow arterial priapism. *J Urol.* 1990; 143: 129-32.
- Bastuba MD, Saenz de Tejada I, Dinlenc CZ, Sarazen A, Krane RJ, Goldstein I: Arterial priapism: diagnosis, treatment and long-term followup. *J Urol.* 1994; 151: 1231-7.
- Levine LA, Guss SP: Gonadotropine-releasing hormone analogues in the treatment of sickle cell anemia-associated priapism. *J Urol.* 1993; 150: 475-7.
- Lue TF: Editorial Comment. *J Urol.* 1988; 139: 737.
- Bertram RA, Webster GD, Carson CC: Priapism: etiology, treatment and results in series of 35 presentations. *Urology.* 1985; 26: 229-32.
- Lowe FC, Jarow JP: Placebo-controlled study of oral

- terbutaline and pseudoephedrine in management of prostaglandine E1-induced prolonged erections. *Urology*. 1993; 42: 51-3.
31. Sidi AA: Vasoactive intracavernous pharmacotherapy. *Urol Clin North Am*. 1988; 15: 95-101.
 32. Potempa D, Juenemann KP, Schuller A, Lšbelenz M, Rassweiler J, Alken P: Die Therapie der prolongierten Erektion. *Akt Urol*. 1991; 143: 933-5.
 33. Rösener M, Wechsel HW, Dichgans J: Intrazerebrale Massenblutung nach intrakavernöser Metaraminol-Behandlung einer prolongierten Erektion. *Akt Urol*. 1995; 26: 427-30.
 34. deHoll JD, Shin PA, Angle JF, Steers WD: Alternative approaches to the management of priapism. *Int J Imp Res*. 1998; 10: 11-4.
 35. Martínez Portillo FJ, Hoang-Böhm J, Weiss J, Alken P, Juenemann KP: Methylene blue as a successful treatment alternative for pharmacologically-induced priapism. *Eur Urol*. 2001; 39: 20-3.
 36. Bush PA, Aronson WJ, Buga GM, Rajfer J, Ignarro LJ: Nitric oxide is a potent relaxant of human and rabbit corpus cavernosum. *J Urol*. 1992; 147: 1650-5.
 37. Furchgott RF: The role of endothelium in the responses of vascular smooth muscle to drugs. *Ann Rev Pharmacol Toxicol*. 1984; 24: 175-97.
 38. Mejean A, Marc B, Rigot JM, Mazeman E: Letter to the editor. *J Urol*. 1993; 149:1149.
 39. Grayhack JT, McCullough W, O'Connor VJ: Venous bypass to control priapism. *Invest Urol*. 1964; 1: 509-13.
 40. Winter CC, McDowell G: Experience with 105 patients with priapism: update review of all aspects. *J Urol*. 1988; 140: 980-3.
 41. Kabalin JN: Corporeal fibrosis as a result of priapism prohibiting function of self-contained inflatable penile prosthesis. *Urology*. 1994; 43: 401-3.

Received: May 5, 2003
Accepted: May 22, 2003

Correspondence address:

Dr. Francisco José Martínez-Portillo
Department of Urology, University
Hospital Schleswig-Holstein
Campus Kiel, Germany
Arnold-Heller-Str. 7
D-24105 Kiel, Germany
Fax: + 49 431 597-1957
E-mail: fmartinez@urology.uni-kiel.d