

RECTOURETHRAL FISTULAS

TOMÁS HANUS

Department of Urology, General Teaching Hospital, First Medical School, Charles University, Postgraduate School of Medicine, Prague, Czech Republic

ABSTRACT

A recent review of the literature shows an increasing number of studies on this subject, most of which are retrospective and presented solely from a clinical point of view. Some of them are no more than case-reports. There is a lack of valid epidemiologic data about the incidence of rectourethral fistulas. According to the literature, these fistulas result from many different causes.

Rectourethral fistulas may have a congenital or acquired origin. Acquired cases include inflammatory, neoplastic, or traumatic etiologies. The diagnostic algorithm is clear and very classical. The new diagnostic approach represents an MRI investigation of the male urethra. It is important to recognize this diversity of etiology because each type requires a different surgical strategy. The aim of the surgical approach is the closure of all types of fistulas. Spontaneous closure of the rectourethral fistulas after double diversion or by means of a one-stage procedure is possible only in a few cases. In most cases, the treatment proceeds in three stages (double diversion–urinary and bowel, closure technique, undiversion). An endoscopic approach using biological sealants seems to be promising. Few urologists and general surgeons have attained wide experience in the management of rectourethral fistulas. No single procedure has been proven most effective or even universally applicable.

Key words: urethra; rectum; abnormalities; fistula; reconstructive surgical procedures
Int Braz J Urol. 2002; 28: 338-45.

CLASSIFICATION OF RECTOURETHRAL FISTULAS

Culp & Calhoon (1) described five basic groups of rectourethral fistulas according to the etiology: congenital, iatrogenic, traumatic, neoplastic, inflammatory.

CONGENITAL RECTOURETHRAL FISTULAS

Endo et al. (2) described the results of a group study of the Japanese Study Group of Anorectal Anomalies (JSGA) to determine the relative incidence of specific types of anorectal anomaly in Japan. This study also discusses the relationship between the levels of the fistula and blind end of the rectum, low

type deformity, rare types, and associated anomalies. A total of 1,992 patients (1,183 boys and 809 girls), registered during the period of 1976 to 1995, were analyzed according to the pathogenesis of anorectal malformation in the field of molecular genetics. Rectovesical fistula and complete covered anus were not infrequent deformities in this series. It is suggested that at least 20% of rectourethral fistula should be categorized as intermediate or low deformity from the viewpoint of the position of the rectal pouch. A significant preponderance of Down's syndrome in cases of deformities without fistula suggests that further investigation of associated anomalies in comparison with other congenital diseases may provide insights.

The purpose of Rintala's study (3) was to compare the long-term outcome of sacroperineal-

sacroabdominoperineal pull-through to that of posterior sagittal anorectoplasty). In boys with high anorectal anomalies, posterior sagittal anorectoplasty is clearly superior to sacroperineal and sacro-abdominoperineal pull-through in terms of long-term bowel function and fecal continence.

ACQUIRED RECTOURETHRAL FISTULAS

In 1972, Smith & Venema (4) reported their 20-year experience with 160 patients who had undergone radical retropubic prostatectomy (RRP) with an incidence of 15 rectal injuries. Only 4 fistulas developed in this group.

The most common single causes of rectourethral fistulas in the series of 23 male patients published by Tiptaft et al. (5) were fracture of the pelvis and iatrogenic causes (including 2 cases after transurethral prostatic surgery, 2 cases after open prostatectomy and 3 cases after urethral instrumentation).

Noldus et al. (6) reported 23 rectal injuries (3.9%) during 589 RRP and cystoprostatectomy (CP).

Eastham & Scardino (7) summarized the incidence of rectal injury during RRP in 3834 patients as 0.7% in average (range 0.2 – 2.9%). Incidence of urethrorectal fistula, as an immediate perioperative complication of open perineal prostate surgery, is 1.4% (8).

Nyam et al. reviewed records of all patients who had rectourethral fistula diagnosed between January 1981 and December 1995. Of the 16 male patients identified, only, all but three had had intervention for their prostatic malignancy performed elsewhere. All patients were interviewed by telephone for follow-up. The average age of those sixteen patients was 68 years. The follow-up covered 80 months in general. Adenocarcinoma of the prostate in 15 patients and recurrent transitional cell epithelioma of the bladder in one patient were the underlying malignant diseases. Seven patients had a radical retropubic prostatectomy, two had radical retropubic prostatectomy after radiation, two had brachytherapy, and three were treated by a combination of radiation and brachytherapy. One patient formed a fistula after cystectomy and dilation of a stricture. This heterogeneous

group of patients received multiple therapies including initial colostomy (7 patients), transanal repair (2 patients), parasacral repair (2 patients), transperineal repair (2 patients), colo-anal anastomosis (3 patients), and muscle transposition (3 patients). Four of those patients required a permanent stoma.

Zippe (9) reviewed preliminary results on prostate cryosurgery and reported a 2% to 5% incidence of rectourethral fistulas. Complications of transrectal ultrasound - guided radical prostate cryosurgery ought to be lower. Porter (10) mentions no urethroperineal fistula and only 2.5% of urethrorectal fistula in 210 patients.

Montorsi et al. (11) reported one complication of prostatorectal fistula after transrectal prostatic hyperthermia (43°C) in patients with advanced prostatic cancer (ten sessions of 60 min each). Fistula was cured by leaving a urethral catheter in place for one month.

Kleinberg et al. (12) summarizes the results of thirty-one patients with stage T1 or T2 prostatic carcinoma following computed tomography - guided transperineal (125) I implants with 47 mCi as the median total activity used. Only one patient developed a prostate - rectal fistula attended to by means of an ileal conduit.

Fengler & Abcarian (13) published the cases of eight patients with recto-urinary fistula in the course of a treatment for prostate cancer (3 fistulas after radiation therapy alone, 3 after prostatectomies and 2 after both surgery and radiation therapy).

Chang et al. (14) published a case of prostatic malakoplakia masquerading as a rectal tumor due to formation of a fistulous tract to the rectal muscular layers.

Cools et al. (15) reported a very uncommon fistula between the large bowel and the prostatic urethra due to Crohn's disease. Felipetto (16) had to treat prostatic cutaneous fistula as a complication of *Pseudomonas* prostatitis.

DIAGNOSTICS OF RECTOURETHRAL FISTULAS

Rectourethral fistulas may be strongly suspected from the patient's history (fecaluria, abnor-

mal urethral discharge, pneumaturia, leakage of urine from the rectum during micturition). The most important diagnostic steps are rectal examination, proctoscopy, careful urethroscopy, intraurethral injection of methylene blue dye, radiopaque contrast agent placed into the bladder and then voided which usually appears in the rectum on X-ray (17-19).

TREATMENT OF RECTOURETHRAL FISTULAS

In many cases, small fistulas will heal “spontaneously” with urinary and/or fecal diversion. Therefore, an initial trial of conservative therapy is reasonable. Select patients with chronic fistulas who are poor surgical candidates may be treated conservatively with antibiotics, pads and symptomatic care. Timing of repair is often individualized -mainly according to the etiology, delay of diagnosis, size of fistula, the first or subsequent repairs, the general condition of the patient, etc. Diversion of urine (suprapubic cystostomy) is mandatory as well as correction of any stricture of urethra distal to the fistula. Fecal diversion, temporary interruption of the fecal stream-colostomy, is used by some as a mandatory part of double diversion or selectively. Gibbons (20) requires a diverting end - colostomy for 3-4 months. As surgeons became more experienced, bowel preparations became standardized, and effective antibiotics were developed, the enthusiasm for colostomy diminished. Currently, colostomy is recommended when antibiotics alone cannot control the inflammation and infection associated with the fistula or when the fistula involves radiated tissue. Low residue diet contributes to healing. Suitable drainage (perineal, urethral splinting) is very important. Two-layer suture of urethra and rectum with suture lines at right angles and with interposition of soft tissue e.g. omentum (21) or gracilis muscle-Ryan et al. (22) or scrotal flap (23) or using other adequate approaches (transabdominal, transvesical, direct exposure of rectourethral fistula through a transperineal incision, transanal, transrectal trans-sphincteric approach or a flap technique with the intact anal sphincter (5,24), or Latzko procedure (6).

Approaches to the urethrorectal fistula repair are listed in Table-1.

Table 1 - Approaches to urethrorectal fistula repair.

Perineal	Young & Stone, 1917 Lewis, 1947 Goodwin, 1958
Posterior-sagittal	Kraske, 1885 Kilpatrick & Thompson, 1962 Kilpatrick & Mason, 1969 (26) Bukowski et al., 1995 (27) Fournier et al., 1996 (28) Fengler & Abcarian, 1997 (13)
	Transanal Parks & Motson, 1983 (24) Tiptaft et al., 1983 (5) Noldus et al., 1970 (6)
Anterior Transanorectal	Gecelter, 1973
Combined	Ali-Ali et al., 1997 (20)
Endoscopic	Wilbert, 1996 Bardari et al., 2001 (29)
Other	Felipetto, 1995 (16) Youssef, 1999 (30) Venkatesh, 1999 (31)

Perineal Approach

In 1917, Young & Stone dissected the rectum away from sphincters, divided the fistula, closed the urethra, and mobilized the rectum further cephalad in such a way as to pull the affected rectum caudad out of the anus where it was then transected and discarded, suturing the proximal rectum to the anal skin. Lewis did not interpose sphincter between the repairs, but did suture the elevator muscle fibers together in the anterior midline when possible.

In 1958, Goodwin et al. (25) reported a series of 22 rectourethral fistulas approached perineally. Extensive mobilization of the rectum posteriorly and the bladder anteriorly through wide perineal exposure allowed interposition of the elevator ani muscles between the urinary tract and rectum.

Posterior-Sagittal Approach

In 1885, Kraske described a posterior mid-line incision extending to the left paramedian aspect of the coccyx and sacrum that required partial sacrectomy in addition to coccygectomy. His method did not involve division of the sphincters, but rather sweeping the rectum laterally to ultimately accomplish resection and reanastomosis of a tumor-bearing rectal segment, thereby preserving fecal continence.

In 1962, Kilpatrick & Thompson used this approach when the rectum was completely mobilized circumferentially proximal and distal to the fistula. The rectourethral fistula was then divided, sparing as much as possible on the urethral aspect. The rectal opening was excised and closed in two layers; the urethra was repaired and stented with a catheter.

Posterior (Parasacrococcygeal) Trans-sphincteric Approach

In 1969, Kilpatrick & Mason (26) improved this method and advocated a more radical procedure of dividing all of the rectal sphincters to give direct access to rectourethral fistula. The procedure (the so-called York Mason approach) is simpler than some complicated transabdominal or transperineal approaches to rectourethral fistula. It is still used because it allows direct visualization of the fistula via parasacrococcygeal (trans-sphincteric) incision especially to fistulae in the mid to lower rectum (13). After skin incision, the mucocutaneous junction is marked with sutures and internal sphincter is exposed. Division of the sphincter mechanism and posterior rectal wall allows exposure of the fistula. Each sphincter muscle is tagged with color-coded sutures. The next step of this procedure is the incision around the fistula, followed by the excision of the fistulous tract, exposing catheter in prostatic urethra. The undermin-

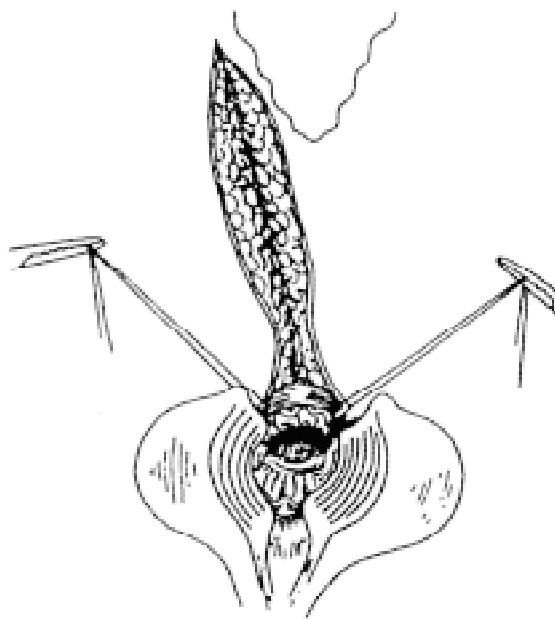


Figure 1 – York-Mason approach to a rectourethral fistula via a parasacrococcygeal (trans-sphincteric) incision. Sutures are used to mark the sphincters. The speculum has been placed at the bottom of the incision and the anterior rectal wall is visible.

ing of rectal wall allows a sufficient mobilization. After the closure of prostatic urethra, the full-thickness rectal wall flaps sutured “vest over pants” technique is recommended. It is important to note that the suture lines do not overlap each other. The procedure is completed by suture of rectal wall and approximation of sphincter muscle (Figure-1).

Fengler & Abcarian (13) succeeded in healing rectourethral fistula in all of 8 patients when they adopted the York Mason approach.

Bukowski et al. (27) treated 7 acquired recurrent rectourethral fistulas (3 after prostatectomy, 3 after trauma and one after perineal abscess) using the York Mason technique.

Fournier et al. (28) reported a similar success in the treatment of one case of urethro-prostate-rectal fistula after gun wound.

Transanal Approach

Parks & Motson (24) popularized the addition of a full thickness local flap of anterior rectal

RECTOURETHRAL FISTULAS

wall as an aid to fistula repair through the intact anal canal (Figure-2). They modified the transanal technique by denuding the rectal mucosa lateral and distal to the fistula, thereby exposing the circular rectal wall away from Denonvilliers' fascia proximal to the fistula for four centimeters. Tiptaft et al. (5) used a special anal retractor for this surgery.

During the Latzko procedure, a fistula is closed in three-layer fashion with absorbable suture. A transurethral catheter is placed for 3 weeks. Noldus et al. (6) reported 23 patients (3.9%) with rectal injury in a total of 589 RRP and CP. Of these 23 patients, 12 developed a rectourethral fistulas, whereas 7 fistulas closed spontaneously by leaving the tran-

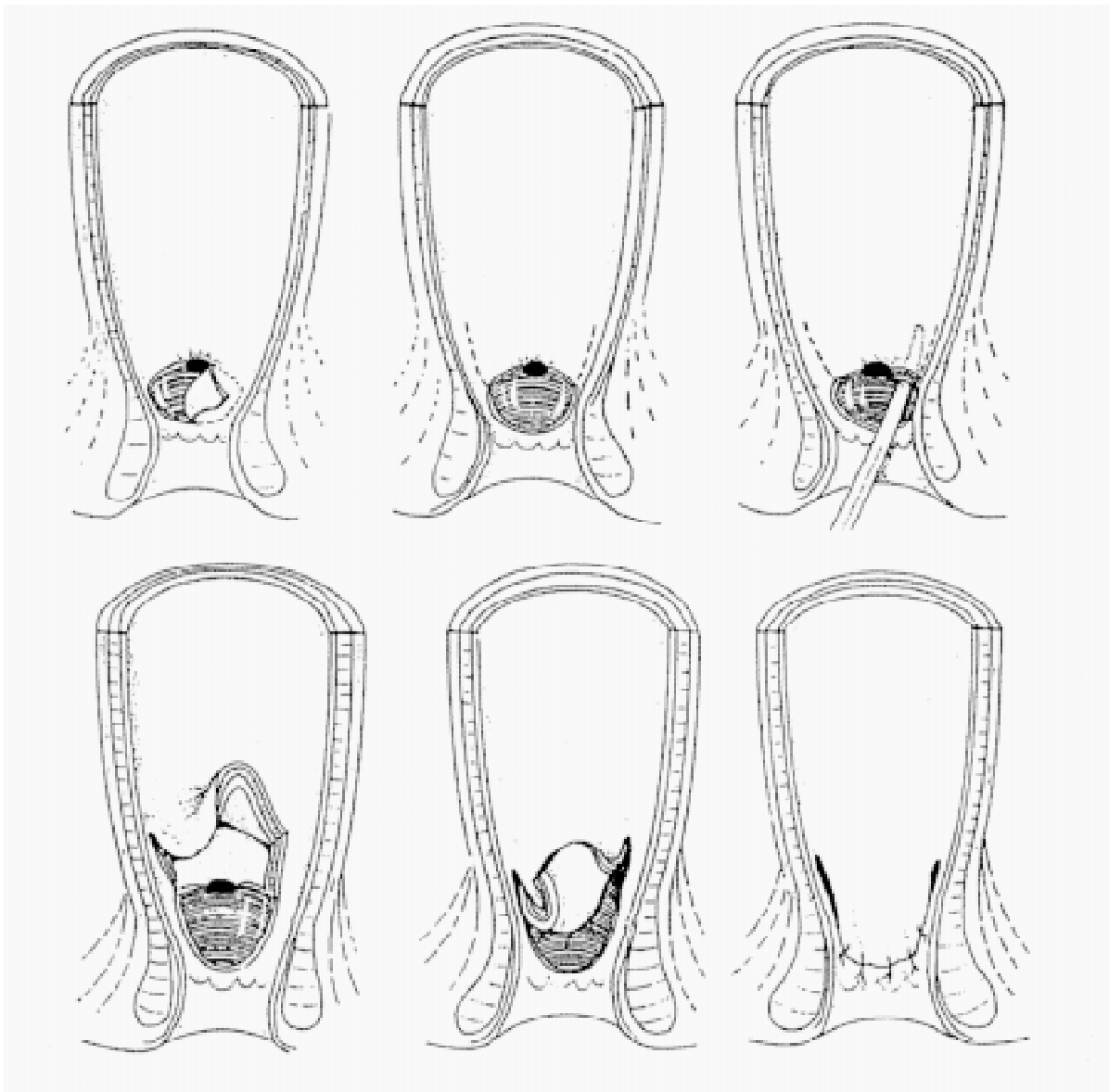


Figure 2 - Rectourethral fistula repair. Full thickness of rectal wall is mobilized to close in a “vest over pants” technique to close the fistula.

surethral catheter in for a longer period. The remaining 5 fistulas were all successfully closed by the transanal Latzko procedure.

Anterior Transanorectal Approach

In 1973, Gecelter performed a midline perineal incision to gain access to the urinary tract after placing the patient in exaggerated lithotomy position. The sphincters were incised anteriorly, carefully placing tagging sutures, and the rectal incision was carried to the fistulous tract, which was excised and repaired in multiple layers with transposition of tissue as available.

Combined Approach

Al-Ali et al. (19) treated 30 men with rectourethral fistulas caused by war wounds. The method of posterior trans-sphincteric-anterior rectal wall advancement was the treatment of choice. Double diversion (end sigmoid colostomy and suprapubic cystostomy) were performed in all patients. Double diversion alone resulted in "spontaneous" rectourethral fistulas healing in 47% of the patients, but 53% of them required reconstruction. Early repair was recommended for large fibrous fistulas. The procedure was performed one month after double diversion. Undiversion was done after two months, when the urethra and anorectal canal were normal.

Endoscopic Approach

Wilbert et al. reported 2 cases of rectourethral fistulas, which were repaired endoscopically. The patients were positioned prone and rectoscope mounted to the operating table was inserted into the rectum. The fistula was visualized and the opening excised to the level of the perirectal tissues with cautery. The rectal wall was mobilized full thickness with scissors and closed primarily in two layers. The patients were then placed in lithotomy position and the urethral side of the fistula was coagulated. Fibrin injection can be applied if necessary.

In 2001, Bardari et al. (29) used biological glue (Glubran®) to close one prostatico-perineal fis-

tula complicating a Miles abdomino-perineal resection of rectum and one persistent neobladder-ileal fistula. The biologic sealant was administered endoscopically through an open-end ureteral catheter 6F.

Other Approaches

Youssef et al. (30) successfully treated 12 male patients, ranging from 7 to 65 years old, who presented urethrorectal fistula from 1990 to 1997 using the perineal subcutaneous dartos pedicled flap procedure. Urethrorectal fistulas resulted from crush pelvic injury (6 cases) and gunshot (2 cases), or were developed after prostatectomy (4 cases). The fistula was associated with urethral stricture in 4 cases. A perineal approach was used in all cases of urethrorectal fistula and combined with the trans-symphyseal approach in the 4 patients with posterior urethral stricture. They interposed a subcutaneous dartos pedicled flap as a vascularized tissue flap between the repaired rectum and urethra. No leakage or perineal collection developed and there was no fistula recurrence. Follow-up ranged from 9 to 42 months. This technique of a perineal subcutaneous dartos pedicled flap may fulfill the requirements for a successful repair of urethrorectal fistula.

Felipetto et al. (16) closed the prostatic cutaneous fistula (as a complication of *Pseudomonas* prostatitis) with human fibrin sealant (Tissucol).

In a prospective study, Venkatesh & Ramanujam (31) discussed the efficacy of autologous fibrin glue application in the healing or closure of recurrent anorectal fistulas. Autologous cryoprecipitate was used as fibrin glue in all patients. This group included complex anorectal fistulas, rectovaginal fistulas, and urethro-vesico-rectal fistulas. Patients were given bowel preparation and intravenous antibiotics before the procedure. Fistulas were curetted before injection of fibrin glue. The success rate reached 60 percent. Patients with urinary tract fistulas and acquired immunodeficiency syndrome failed to respond. No major complications ensued. The results of fibrin glue application in this small series of recurrent fistulas are inspiring. This fibrin glue can be used as an outpatient procedure since it is a minimally invasive technique, without any significant complications. It

can be offered as an alternative to conventional surgery in recurrent fistulas.

CONCLUSIONS

The possibility of euro-rectal fistula must be acknowledged. A careful history of the patient has to be taken into account. Standard urologic evaluation is mandatory. Proctoscopy, colonoscopy and cystoscopy are inevitable investigations. There is a choice of surgery techniques for the closure of fistulas. Surgery of rectourethral fistulas is technically demanding and requires collaboration with rectal surgeons.

REFERENCES

1. Culp OS, Calhoon HW: A variety of rectourethral fistulas: experiences with 20 cases. *J Urol.* 1964; 91: 560.
2. Endo M, Hayashi A, Ishihara M, Maie M, Nagasaki A, Nishi T, Saeki M: Analysis of 1,992 patients with anorectal malformations over the past two decades in Japan. Steering Committee of Japanese Study Group of Anorectal Anomalies. *J Pediatr Surg.* 1999; 34: 435-41.
3. Rintala RJ, Lindahl HG: Posterior sagittal anorectoplasty is superior to sacroperineal-sacroabdominoperineal pull-through: a long-term follow-up study in boys with high anorectal anomalies. *J Pediatr Surg.* 1999; 34: 334-7.
4. Smith AM, Veenema RJ: Management of rectal injury and rectourethral fistulas following radical retropubic prostatectomy. *J Urol.* 1972; 108: 778.
5. Tiptaft RC, Motson RW, Costello AJ, Paris AME, Blandy JP: Fistulae involving rectum and urethra: the place of Park's operations. *Brit J Urol.* 1983; 55: 711-5.
6. Noldus J, Graefen M, Huland H: An "old technique" for a new approach for repair of rectourinary fistulas. *J Urol.* 1997, 157 (suppl. 4): 1547.
7. Eastham JA, Scardino PT: Radical Prostatectomy. In: Walsh PC, Retik AB, Vaughan ED, Wein AJ (eds.). *Campbell's Urology.* Philadelphia, WB Saunders Co., 7th ed., 1997, p. 2554.
8. Thomas R, Davis R, Ahuja S: Toward out-patient radical prostatectomy: a cost effective cost management of patients with localized prostate cancer. *Brit J Urol.* 1997; 80 (suppl. 2): 261.
9. Zippe CD: Cryosurgery of the prostate: technique and pitfalls. *Urol Clin North Am.* 1996; 23: 147-63.
10. Porter AT, Littrup P, Grignon D, Forman J, Montie JE: Radiotherapy and Cryotherapy for Prostate Cancer. In: Walsh PC, Retik AB, Vaughan ED, Wein AJ (eds.). *Campbell's Urology.* Philadelphia, WB Saunders Co., 7th ed., 1997 p. 2605.
11. Montorsi F, Guazzoni G, Bergamaschi F, Galli L, Colombo R, Consonni P et al.: Transrectal prostatic hyperthermia and advanced prostatic cancer: Clinical results of one year follow up. *Acta Urol. Ital.* 1992; 6 (Suppl. 6): 471-4.
12. Kleinberg L, Wallner K, Roy J, Zelefsky M, Arterbery VE, Fuks Z et al.: Treatment-related symptoms during the first year following transperineal (125)I prostate implantation. *Int J Radiat Oncol Biol Phys.* 1994; 28: 985-90.
13. Fengler SA, Abcarian H: The York Mason approach to repair of iatrogenic rectourinary fistulae. *Am J Surg.* 1997; 173: 213-7.
14. Chang KM, Lee RC, Ciu AW, Wang JH, Chiang H: Malakoplakia of the prostate forming a fistulous tract to rectum: a case report. *Chung-Hua-I-Hsueh-Tsa-Chih-Taipei.* 1996; 58: 439-43.
15. Cools P, Vanderputte S, Van der Stighelen Y, Colemont L, Denis B: Rectourethral fistula due to Crohn's disease. *Acta Urol Belg.* 1996; 64: 47-8.
16. Felipetto R, Vigano L, Cecchi M, Florentini L, Minervini R: Use of fibrin sealant in the treatment of prostatic cutaneous fistula case of *Pseudomonas* prostatitis. *Int Urol Nephrol.* 1995; 27: 563-5.
17. Blandy JP, Singh M: Fistulae involving the adult male urethra. *Br J Urol.* 1972; 44: 632.
18. Chiou RK, Anderson JC, Tran R, Patterson RH, Wobig R, Taylor RJ et al.: Evaluation of urethral strictures and associated abnormalities using resolution and color Doppler ultrasound. *Urology.* 1996; 47: 102-7.
19. Al-Ali M, Kashmoula D, Saoud IJ: Experience with 30 posttraumatic rectourethral fistulas: presentation of posterior transsphincteric anterior rectal wall advancement. *J Urol.* 1997; 158: 421-4.
20. Gibbons RP: Radical Perineal Prostatectomy. In: Walsh PC, Retik AB, Vaughan ED, Wein AJ (eds.). *Campbell's Urology.* Philadelphia, WB Sanders Co., 7th ed., 1997, pp. 2589-603.
21. Turner-Warwick R: The use of the omental pedicle graft in urinary reconstruction. *J Urol.* 1976; 116: 341.
22. Ryan JA Jr, Beebe HG, Gibbons RP: Gracilis muscle flap for closure of rectourethral fistula. *J Urol.* 1979; 122: 1242.

23. Venable DD: Modification of the anterior perineal transorectal approach for complicated prostatic urethrorectal fistula repair. *J Urol*. 1989; 142: 381-4.
24. Parks AG, Motson RW: Peranal repair of rectoprostatic fistula. *Brit J Surg*. 1983; 70: 725.
25. Goodwin WE, Turner RD, Winter CD: Rectourinary fistula: principles of management and a technique of surgical closure. *J Urol*. 1958; 80: 246.
26. Kilpatrick FR, Mason AY: Postoperative recto-prostatic fistula. *Brit J Urol*. 1969; 41: 649-51.
27. Bukowski TP, Chakrbarty A, Powell IJ, Frontera R, Perlmutter AD, Montie JE: Acquired rectourethral fistula: Method of repair. *J Urol*. 1995; 153: 730.
28. Fourniér R, Traxer O, Lande P, Tuech JJ, Vergos M: Posterior trans-anal-sphincter approach in the management of urethro-prostate-rectal fistula. *J Urol [Paris]*. 1996; 102: 75-8.
29. Bardari F, D'Urso L, Leggero R, Coppola P, Muto G: Conservative treatment of iatrogenic urinary fistulas: the value of a new synthetic biological glue (GLUBRAN). *Eur Urol*. 2001; 39 (suppl .5): 297.
30. Youssef AH, Fath Alla M, El-Kassaby AW: Perineal subcutaneous dartos pedicled flap as a new technique for repairing urethrorectal fistula. *J Urol*. 1999; 161: 1498-500.
31. Venkatesh KS, Ramanujam P: Fibrin glue application in the treatment of recurrent anorectal fistulas. *Dis Colon Rectum*, 1999; 42: 1136-9.

Received: January 22, 2002

Accepted: February 22, 2002

Correspondence address:

Dr. Tomáš Hanuš
Department of Urology, Charles University
Ke Karlovu 6
128 08 Prague 2
Czech Republic