

TRANSPERITONEAL LAPAROSCOPIC NEPHRECTOMY IN CHILDREN: SURGICAL TECHNIQUE WITH 3 TROCARS

ROBERTO K. B. MIURA, CARLOS E. R. JUNQUEIRA, LEOLINDO TAVARES, ROBERTO R. MAROCLO, ROGÉRIO DE M. MATTOS, RONALDO DAMIÃO

Section of Urology, State University of Rio de Janeiro (UERJ), and Cardoso Fontes Municipal Hospital, Rio de Janeiro, RJ, Brazil

ABSTRACT

Introduction: The first videolaparoscopic nephrectomy in children was performed in 1992, and since then, little experience, and small series of pediatric patients have been reported. The technique, described by Clayman and accepted worldwide, requires the insertion of 4 or 5 trocars. Introduction of trocars is an important cause of complication in videolaparoscopic surgery. The authors report laparoscopic transperitoneal nephrectomy in children using only 3 trocars, to minimize risk of vascular injury or visceral perforation.

Surgical Technique: The patient is placed in supine position with flank rotated at approximately 45°. After pneumoperitoneum is established, the first trocar is introduced in umbilicus for the laparoscope. Under direct vision, the second trocar is placed at ipsilateral midclavicular line, and the third and last trocar in the epigastric region. Laparoscopic transperitoneal nephrectomy was performed in 3 children aged 7, 8, and 14 years old. Right nephrectomy was performed in 2 cases, and left nephrectomy in one. Mean operative time was 163 min (100 to 230 min), and no transfusion was necessary. Patients were discharged from hospital on day 2 to 4 after the procedure. There were no conversions to open surgery, and no intra or postoperative complications.

Comments: Every trocar and instrument introduction into the abdominal cavity presents an important risk of vascular injury or visceral perforation. The risk per patient is naturally increased with the number of trocars utilized. Injuries during laparoscopic procedures can theoretically damage every intra- or retroperitoneal organ. The majority of these lesions will need immediate or delayed open surgery, due to hematoma formation, postoperative bleeding, abscess, or peritonitis. Transperitoneal videolaparoscopic nephrectomy in children can be performed using only 3 trocars. The technique allows a better cosmetic result, and reduces the risk of trocar introduction injuries, like vascular and visceral lesions.

Key words: kidney; nephrectomy; laparoscopy; children

Int Braz J Urol. 2002; 28: 346-8

INTRODUCTION

The introduction of videolaparoscopic surgery brought a new dimension to surgical practice. In urologic scope, laparoscopic procedures are performed only in few centers, especially in children, for which this technique was described to the diag-

nosis of cryptorchidism, intersexual disorders, and gonadectomy (1).

Even though the first laparoscopic nephrectomy in children has been performed in 1992 (1), at present little experience and small series have been published (2,3), and the most diffused technique needs the introduction of 4 or 5 trocars (2,3).

Injuries due to trocar insertion are major and potential complications of the laparoscopic technique, comprehending from visceral injuries to serious vascular trauma (4,5). The authors describe the transperitoneal laparoscopic nephrectomy technique in children performed with only 3 trocars.

SURGICAL TECHNIQUE

Patients were admitted on the day before surgery and were not submitted to a specific bowel preparation, only an 8 hour fasting. Antimicrobial prophylaxis with 1st generation cephalosporin was administered before the procedure. After general anesthesia, nasogastric and bladder tubes were inserted. Patients were placed in supine position, with the flank in 45° elevation in the side to be operated.

A small circular incision in the inferior umbilicus edge was made, the rectus abdominalis aponeurosis was fixed, and the Veress needle was introduced. The pneumoperitoneum was established with 12-mm. Hg and the first 10-mm. trocar was introduced for the 30° optical insertion. The second 12-mm. trocar was placed under direct vision at the midclavicular line in the ipsilateral flank, and the third and last 5-mm. trocar in the epigastric region (Figure-1).

Nephrectomy itself was performed by incision of the paracolic gutter, with medial mobilization of the ascendant colon for right nephrectomy, and

mobilization of the descendent colon for left nephrectomy; anterior renal fascia opening and identification of the renal parenchyma and ureter during lower pole dissection. Ureter was clipped, divided, and fixed to facilitate approaching renal hilus, without being necessary introducing a fourth trocar for kidney traction and major vascular exposure.

Renal pedicle was approached with dissection, clipping and division of renal artery and vein individually. Both arterial and vein duplications may exist, and if a large vein is found, endoscopic vascular staplers, as Endo-GIA, can be used for a safe ligation. Then proceed to kidney upper pole dissection and removal of surgical specimen. The cavity was revised with special care to renal bed hemostasis. Surgical specimens were removed through 12-mm. incision, after been placed in an endo-bag.

Three children aged 7, 8 and 14 years old underwent a transperitoneal videolaparoscopic nephrectomy using this technique. Two of them were male and one was female. All had urinary tract infection and the radiologic exams (ultrasonography, urography, and cintigraphy) showed lost of renal unity.

None was submitted to previous renal or ureteral surgery, and in all cases, adrenal glands were carefully preserved. Right nephrectomy was performed in 2 cases, and left nephrectomy in one, and no surgical field draining was performed in any of them.

Operating time ranged from 100 to 230 minutes (mean 163 minutes). Patients were discharged between postoperative days 2 and 4. There were no intra- or postoperative complications, and no patient required a blood transfusion. Patients are in medical follow up and returned to their normal activity on day 10 after the surgery.

COMMENTS

Trocar and other instruments insertion in abdominal cavity present an important risk of vascular injury or visceral perforation. The risk per patient is naturally increased with number of trocars utilized. Based on videolaparoscopic splenectomy with 3 trocars experience, this technique has been recently performed for nephrectomy aiming to achieve a lower risk (4).

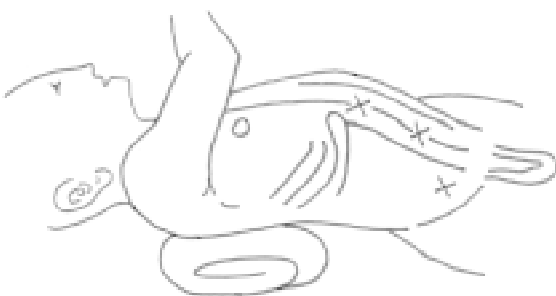


Figure 1 - Patient in supine position, with the flank in 45° elevation in the side to be operated. Trocars are placed in umbilicus (10-mm.), hemiclavicular line (12-mm.) and epigastric region (5-mm.).

Desgrandchamps et al. (4) reported videolaparoscopic nephrectomy results in 20 patients using only 3 trocars. In this study, operative time was similar for 3 and 5 trocars use, indicating that reducing the number of instruments did not make performing the same laparoscopic procedures more difficult (4).

Injuries during laparoscopic procedures can theoretically affect any intra- or retroperitoneal organ. Most of these injuries will need immediate or delayed open surgery conversion, due to hematoma formation, postoperative bleeding, abscess, or peritonitis. Bowel, gastric and colonic injuries, when not identified, lead to major complications as ileus, peritonitis and abdominal sepsis (5). Safety device trocars were developed to prevent risks of visceral and vascular perforation, even though these are not 100% safe (5).

When detecting a visceral injury, the surgeon may decide if it can be laparoscopically restored or if an immediate conversion to a laparotomy is required. The injury will be limited when an appropriate and immediate treatment is established.

Transperitoneal videolaparoscopic nephrectomy in children can be performed using only 3 trocars. The technique provides better cosmetic re-

sults, lesser surgical trauma and reduces the risk of injuries related to trocar insertion, as vascular and visceral lesions.

REFERENCES

1. Ehrlich RM, Gershman A, Mee S, Fuchs G: Laparoscopic nephrectomy in a child: expanding horizons for laparoscopy in pediatric urology. *J Endourol.* 1992; 6:463-5.
2. Gillick J, Mohla DJ, Nicholas JL, Fitzgerald RJ: Pediatric laparoscopic nephrectomy: review of 5 years experience at three centers. *Pediatr Endosurg Innov Techn.* 2000; 4:237-41.
3. Borer JG, Atala A: Endoscopic retroperitoneal nephrectomy. *Pediatr Endosurg Innov Techn.* 2000; 4:229-36.
4. Desgrandchamps F, Gossot D, Jabbour ME, Meria P, Teillac P, Le Duc A: A 3 trocar technique for transperitoneal laparoscopic nephrectomy. *J Urol.* 1999; 161:1530-2.
5. Fahlenkamp D, Rassweiler J, Fornara P, Frede T, Loening SA: Complications of laparoscopic procedures in urology: experience with 2,407 procedures at 4 German centers. *J Urol.* 1999; 162:765-71.

Received: October 2, 2001

Accepted after revision: May 5, 2002

Correspondence address:

Dr. Roberto Kazumi Baldas Miura
Av. das Américas, 5001 / 226
Rio de Janeiro, RJ, 22631-004, Brazil
Tel.: + 55 21 2432-7828