



Voiding Chain Cystourethrography: Assessing A Historical Test's Role in Selection for Urethrolisis

Steven P. Petrou, Karen Ryan, Dorothea Metz-Kudashick, Michael G. Heckman, David D. Thiel

Department of Urology (SPP, DDT); Department of Radiation and Oncology (KR), and Section of Biostatistics (MGH) Mayo Clinic, Jacksonville, Florida, USA; No affiliation (DMK)

ABSTRACT

Objective: To analyze the benefit of voiding chain cystourethrography (VCC) [placing a radiographic opaque chain into the urethra and bladder and asking the patient to void under fluoroscopy] in the urodynamic evaluation of female bladder outlet obstruction (BOO).

Materials and Methods: Females with post anti-incontinence operation voiding dysfunction who underwent urodynamic evaluation augmented with VCC and later had urethrolisis were identified. Six diagnostic criteria for obstruction were applied to each patient: (1) VCC (obstructed: chain was angulated and could not be voiding out) (2) Video urodynamic study (VUDS) (detrusor contraction combined with radiographic obstruction) (3) maximum flow (Q_{max}) ≤ 15 cc/sec, detrusor pressure (pDet)@ $Q_{max} \geq 20$ cm H₂O (4) $Q_{max} \leq 11$ cc/sec, pDet@ $Q_{max} \geq 25$ cm H₂O (5) $Q_{max} \leq 12$ cc/sec, pDet@ $Q_{max} \geq 25$ cm H₂O (6) Blaivas-Groutz (B-G) nomogram. Urethrolisis results were reviewed. Agreement in assessment of BOO criteria was assessed by estimating the proportion of pair-wise agreements along with an exact binomial 95% confidence interval (CI) and by estimating kappa along with a 95% CI.

Results: Twenty-one patients were identified. Twenty of the 22 urethrolyses (91%) were clinically successful. Diagnosis of BOO was most common for VCC (86%) and then B-G Nomogram (67%). Agreement with the VCC was relatively poor for each of the five other methods (14%-62%) with the video urodynamic study (VUDS) being the best. Three patients with successful urethrolisis were diagnosed only by the VCC. All of kappa values regarding agreement with the VCC were low; the highest value of 0.15 was observed for VUDS.

Conclusion: VCC may augment selection criteria for urethrolisis.

ARTICLE INFO

Key words:

Female; Ureteral Obstruction; Urodynamics; Urinary Incontinence

Int Braz J Urol. 2013; 39: 498-505

Submitted for publication:
January 30, 2013

Accepted after revision:
June 14, 2013

INTRODUCTION

Selection for urethrolisis in symptomatic females with a history of an anti-incontinence procedure may be challenging, especially in the absence of immediate temporal association and/or with a history of previous failed urethrolisis. While recognizing the value of the various pressure flow criteria developed for female bladder ou-

tlet obstruction (BOO), our clinic relies principally on the video urodynamic appearance of the bladder and urethra with voiding as described by Nitti et al. (1) and the Blaivas Groutz (B-G) nomogram (2). In some patients with a high index of clinical suspicion, the pressure flow criteria for obstruction were not strictly met and/or it was difficult to identify the urethra during testing. One example would be patients that voided with minimal or

no detrusor contraction. To augment the evaluation and radiographic appearance of the urethral and bladder anatomy we incorporated the use of a historical test, the voiding chain cystourethrogram (VCC). We report on our experience using this classic historical test (3) in selection for urethrolysis.

MATERIALS AND METHODS

IRB approval was obtained for this retrospective review of 21 patients who underwent urethrolysis performed by a single surgeon and had VCC as part of their video urodynamic study (VUDS) for voiding dysfunction following an anti-incontinence procedure. All patients underwent a complete preoperative clinical and videourodynamic evaluation including a catheter free uroflow and catheterized post-void residual videourodynamics with pressure flow analysis, and fluoroscopically visualized VCC.

Urodynamic Evaluation

Video urodynamic study (VUDS) was completed using a multi-channel 7F transurethral catheter and a rectal air charged catheter. The filling portion of the cystogram was performed at 50 mL per minute using contrast medium. Where clinically needed (e.g. severe sensory urgency/detrusor overactivity/small capacity bladder), the fill rate was reduced to 12.5 - 25 mL per minute. Intermittent fluoroscopic imaging was utilized to quantify trabeculation, vesicoureteral reflux, and voiding anatomy. During the voiding portion of the study, the patient was asked to void to the best of her ability. If the patient was unable to generate an uroflow, the maximum detrusor pressure generated was quantified. Notation was made of the patient's voiding characteristics such as voiding with a detrusor contraction, Valsalva maneuvers, or a combination of both. The patient then underwent VCC using the below technique.

Voiding chain cystography technique

The urodynamics (UDS) catheter was removed, and the bladder was filled with approximately 250ml of diluted Omnipaque (G.E.

Healthcare, Inc., 25 ml contrast with 100 ml sterile water) using a sterile 14Fr catheter. Dilution optimized visualization of the chain through the contrast. After the instillation catheter was removed, the cystourethrogram chain was dipped in 2% lidocaine and inserted into the urethra using a rounded forceps. The chain used was a 14kt gold (rhodium-plated) link chain measuring 60 mm in length and 2.15 mm in width; it weighs approximately 7.40 grams and has one round link on each end; the end links have an outside diameter of 5.00 mm and an inside diameter of approximately 3.20 mm (Figure-1). The chain was secured with tape loosely to the inner leg.

The UDS table was elevated to 90 degrees and the patient was turned to the side, using fluoroscopy to check chain placement. The patient was radiographically examined while coughing, with Valsalva maneuvers, and with voiding. The VCC was used to identify the bladder, bladder neck, and urethral position (including the presence or absence of urethral angulation) during voiding, and notation was made whether the patient was able to void the chain out of the bladder with micturition (Figures 2-4). The VUDS data was retrospectively analyzed separately by multiple criteria for female BOO.

Figure 1 - Demonstrates the 14kt gold (rhodium-plated) link chain measuring 60mm in length and 2.15mm in width; it weighs approximately 7.40 grams and has one round link on each end; the end links have an outside diameter of 5.00 mm and an inside diameter of approximately 3.20 mm.

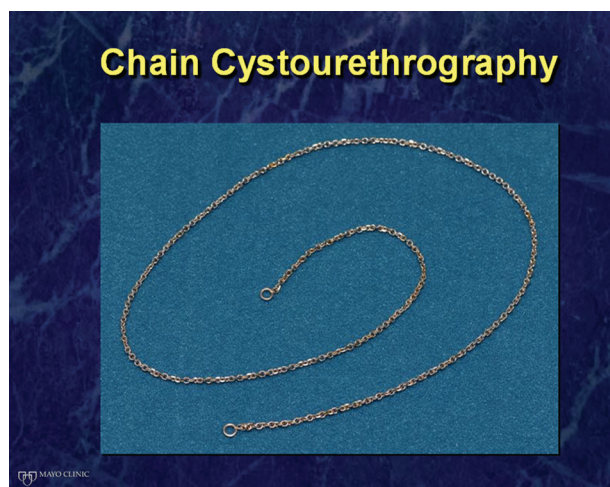


Figure 2a and 2b - shows the chain in position for the VCC and then the chain angulation with the attempted voiding during the VCC. Figure 2a – white arrow shows chain in urethra with the patient relaxed. Figure 2b - white arrow shows angulation of chain, consistent with obstruction during voiding attempt with VCC.

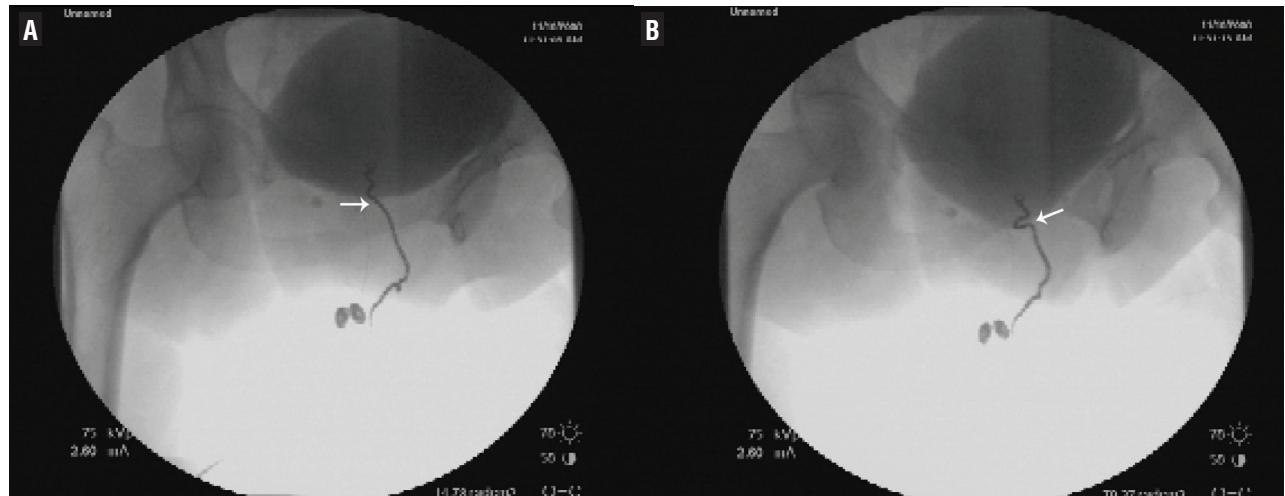
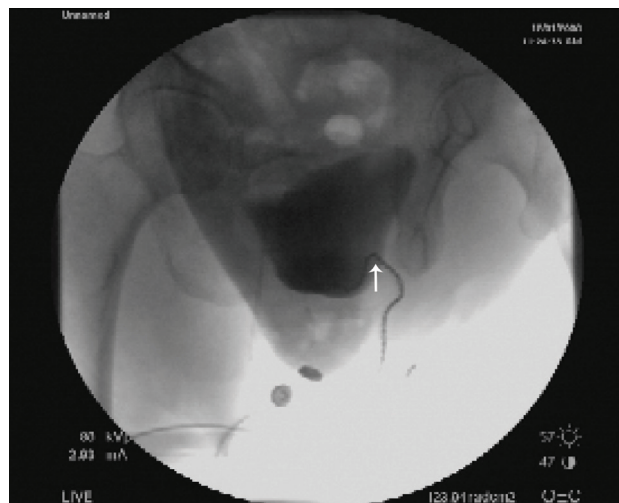


Figure 3 - Demonstrates chain angulation from a VCC test that is consistent with obstruction. White arrow shows chain angulation consistent with obstruction from patient with previous suburethral sling.



Criteria for obstruction:

1. UDS obstruction: radiographic evidence for obstruction between the bladder and distal urethra with a sustained detrusor contraction (1,4);
2. Maximum flow (Q_{max}) ≤ 15 cc/sec, detrusor pressure (pDet) @ Q_{max} ≥ 20 cm H₂O (Pressure Flow Criterion 1) (5);

3. $Q_{max} \leq 11$ cc/sec, pDet @ $Q_{max} \geq 25$ cm H₂O (Pressure Flow Criterion 2) (6);
4. $Q_{max} \leq 12$ cc/sec, pDet @ $Q_{max} \geq 25$ cm H₂O (Pressure Flow Criterion 3) (7);
5. Blaivas-Groutz nomogram obstructed (2);
6. VCC obstructed: a combination of radiographic chain angulation and inability to void the chain out on command (Figures 2a, 2b and 3).

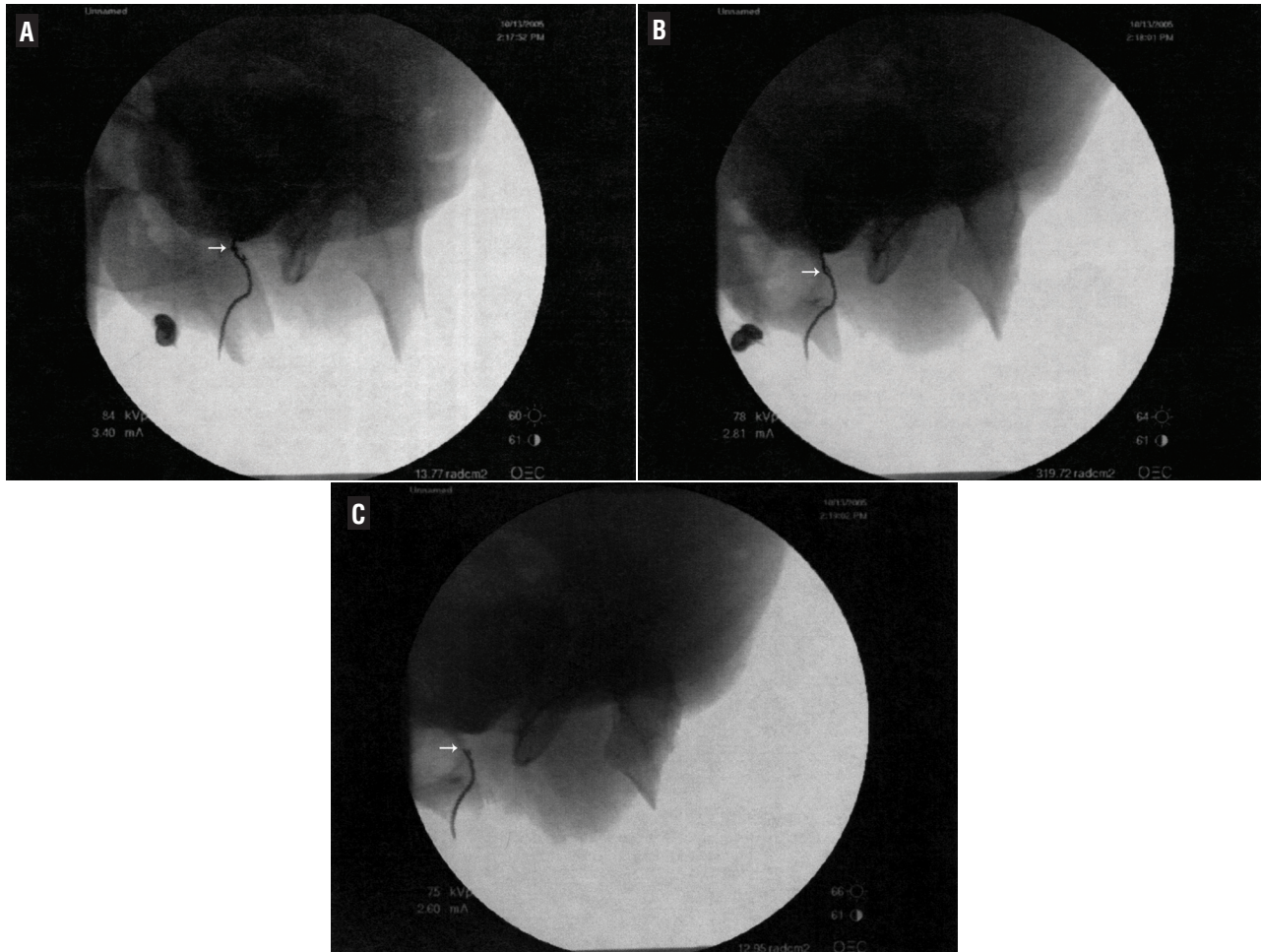
Successful urethrolysis was determined by resolution of presenting urinary complaints and normalization of physical examination including the absence of urethral tethering.

Statistical analysis

Post-void residual values were compared before and after surgery using a Wilcoxon signed rank test.

Agreement in assessment of BOO between the VCC and each of the five other methods was assessed by estimating the proportion of pair-wise agreements along with an exact binomial 95% confidence interval (CI), and also by estimating kappa along with a 95% CI. All statistical analyses were performed using SAS (version 9.2; SAS Institute, Inc., Cary, North Carolina).

Figure 4a, 4b, and 4c - Reveals a VCC test that is consistent with no obstruction: the chain in place, voiding without angulation and then being voided from the bladder. Figure 4a reveals chain in urethra with the patient relaxed, with no angulation. Figure 4b shows patient beginning to void, white arrow shows no angulation. Figure 4c - white arrow shows chain being expelled from urethra with voiding, consistent with no obstruction.



RESULTS

A total of 21 female patients who underwent a video urodynamic study for voiding dysfunction and went on to have urethrolysis were considered for inclusion in this study. Median age was 65 years (Range: 43 - 83 years). One patient in the series had an unsuccessful urethrolysis and underwent a second successful urethrolysis; only the set of measurements corresponding to the first urethrolysis were considered in these analyses in order to satisfy the statistical assumption of independent measurements. Twenty of the 22 opera-

tions (91%) were classified as having a clinically successful urethrolysis based on postoperative clinical evaluation and return of normal voiding habits. Preoperative post-void residual assessment revealed a median of 115 cc's (Range: 10 - 720), with a mean of 178 cc's. For the postoperative post-void residual measurements, the median was 50 cc's (Range: 3 - 170), and the mean of 57 cc's. When evaluating the difference between the post vs. presurgical values, the median difference was -76 (Range: -640 to 43), and the mean was -120. There was strong evidence of a difference between the pre and post measures ($P < 0.001$).

A summary of assessments of BOO for each of the six different methods is provided in Table-1. An assessment of BOO was most common for the VCC (86%), followed by the B-G Nomogram (67%). One patient was rated as obstructed by all six methods; she later had a successful urethrolysis. Four patients had no detrusor contraction noted on urodynamic evaluation but were obstructed by VCC, three had successful urethrolysis and one patient did not.

An evaluation of agreement regarding BOO between the VCC and each of the five other methods is displayed in Table-2. Agreement with the VCC was relatively poor for each of the five individual methods but was best for the VUDS, where assessment of obstruction was the same as

the VCC for 13 of the 21 patients (62%). The B-G nomogram had the next highest agreement with the VCC; assessment of obstruction was the same as the VCC for 11 patients (52%). Agreement with the VCC was particularly poor for $Q_{\max} \leq 15$ cc/sec, pDet@ $Q_{\max} \geq 20$ cm H₂O, $Q_{\max} \leq 11$ cc/sec, pDet@ $Q_{\max} \geq 25$ cm H₂O, and $Q_{\max} \leq 12$ cc/sec, pDet@ $Q_{\max} \geq 25$ cm H₂O, where assessment of obstruction was the same as the VCC for between 14% and 33% of patients. All values of kappa regarding agreement with the VCC were quite low; the highest value of 0.15 was observed for VUDS.

Although it is of interest to evaluate whether any of the six measures of BOO are associated with the unsuccessful urethrolysis patients (2/22), such analysis was impossible due to the very small

Table 1 - Assessment of bladder outlet obstruction by six different methods.

Method	No. (%) of assessments of bladder outlet obstruction (N = 21)
VCC	18 (86%)
VUDS	12 (57%)
$Q_{\max} \leq 15$ cc/sec, pDet@ $Q_{\max} \geq 20$ H ₂ O	8 (38%)
$Q_{\max} \leq 11$ cc/sec, pDet@ $Q_{\max} \geq 25$ H ₂ O	7 (33%)
$Q_{\max} \leq 12$ cc/sec, pDet@ $Q_{\max} \geq 25$ H ₂ O	4 (19%)
B-G nomogram	14 (67%)

Table 2 - Agreement in assessment of bladder outlet obstruction between the VCC and five other methods.

Measure of obstruction	Agreement with VCC assessment of obstruction		
	Kappa (95% CI)	Fraction (%) of agreement	95% CI
VUDS	0.15 (-0.19, 0.49)	13/21 (62%)	38% - 82%
$Q_{\max} \leq 15$ cc/sec, pDet@ $Q_{\max} \geq 20$ H ₂ O	-0.14 (-0.42, 0.14)	7/21 (33%)	15% - 57%
$Q_{\max} \leq 11$ cc/sec, pDet@ $Q_{\max} \geq 25$ H ₂ O	-0.15 (-0.43, 0.13)	6/21 (29%)	11% - 52%
$Q_{\max} \leq 12$ cc/sec, pDet@ $Q_{\max} \geq 25$ H ₂ O	-0.19 (-0.47, 0.10)	3/21 (14%)	31% - 36%
B-G nomogram	-0.25 (-0.47, -0.03)	11/21 (52%)	30% - 74%

number of patients who experienced this outcome. For the first patient with unsuccessful urethrolysis, the only test with an assessment of obstruction was the VCC, while the only test with an assessment of obstruction for the second patient was the VUDS.

DISCUSSION

The challenge in diagnosing BOO in females is well documented in the literature with the symptoms being quite variable (i.e. obstructive, irritative, or a combination of both) (8-11). Further complicating matters is the variable personal nature of female voiding habits. Consequently, physicians often rely on the temporal association of voiding dysfunction to an anti-incontinence operation to initiate evaluation and/or offer therapy (8,12,13). When patient history or time frame does not offer this diagnostic advantage, more thorough evaluation is warranted than just proceeding to urethrolysis, especially if she has already had a history of that operation (14). The complex nature of female voiding dysfunction may require additional parameters besides pressure-flow criteria (1-7,15). We desired to see if the VCC, as a non-pressure-flow based test, would assist in positively predicting those patients that would have a successful urethrolysis. Radiographic imaging will potentially not clearly illuminate a urethral obstruction, secondary to the air, soft tissue interface or the absence of a well-defined detrusor contraction (16). Consequently, we tried to overcome this problem by resurrecting the use of the urethral chain to look for an angulation or point of obstruction. Past physicians have described the use of the urethral chain when evaluating female voiding dysfunction. Stevens and Smith noted that in certain settings, placing a chain into the urethra may provide distinct advantages over the use of contrast medium while others noted that a chain may be less distorting than a rubber catheter in assessing urethrovesical anatomy (17,18). Chain cystogram was described by Hodgkinson in 1953 to study urethrovesical relationships in order to classify types of female stress incontinence (19). However, it was later discovered that chain cystogram alone had a 50 percent margin of error and 65 percent of continent controls had positive fin-

dings (16). Nevertheless, we found the chain was an excellent adjunct for assisting with urethral radiographic visualization. We came to learn that not only was the configuration of the chain important, but that the ability to void the chain out was an added finding when dealing with obstruction: the ability to push the chain out served as a proxy to gauge voiding efficacy in patients that voided with abdominal straining and not a true detrusor contraction. That four of the 21 patients evaluated failed to generate a detrusor contraction during urodynamic testing but were obstructed by VCC criteria with three having a successful urethrolysis reveals the potential value of the test capturing treatable patients by, at the minimum, reinforcing clinical intuition.

VCC definition of obstruction itself had the highest agreement with the video urodynamics definition of obstruction (1,4). This may be due to the similarity between the tests as a urethral imaging based study. Table-1 confirms that 18 of the 21 patients that underwent urethrolysis were rated as non-obstructed by at least one of the methods, but VCC rated the fewest number of patients as non-obstructed (3/21). In one of those three cases, the chain was radiographically angulated, but the patient was able to void the chain out with difficulty and concentrated effort thus technically making the VCC test negative (which required failure to expel the chain with voiding). Despite that observation, secondary to temporal association, physical exam and other criteria positivity, the patient was offered and underwent a successful urethrolysis. In another patient with negative criteria including the VCC but with a positive B-G nomogram, surgery again was offered secondary to clinical suspicion of temporal association. She underwent a later unsuccessful urethrolysis.

A potential criticism of this study may be that if patients seemed to do well with urethrolysis regardless of the parameter used to define obstruction, is this test really one of additive value? We counter that in cases with a challenging diagnosis, additional objective data has inherent value and will help reinforce clinical suspicion. Another criticism is that perhaps the VCC had the highest diagnostic capture rate secondary to its use on patients that we were confident were obstructed

and were thus looking for a test to confirm our intuition. Postoperative pressure-flow urodynamic studies would have been of value to further evaluate the sensitivity of the test for obstruction; nevertheless, this was not able to be completed secondary to this study being a retrospective review and the lack of desire of patients to undergo testing in the event of a good clinical result at the time of their treatment course.

The variable nature of female voiding patterns solidifies the drive for diagnostic accuracy and confirmation of clinical suspicion. Patients readily grasp both the concept of radiographic chain angulation when gazing upon the X-ray monitor and the ability/inability to successfully void the chain. Perhaps the VCC should not return from its historical past as a standalone test but to be resurrected when needed and combined with the other methods of evaluation. We will continue to utilize VCC secondary to the above reasoning when faced with clinical suspicion and variable findings of obstruction on urodynamic evaluation (15).

CONCLUSIONS

The voiding chain cystourethrogram may help confirm clinical suspicion and serve as an adjunct to urodynamic testing in female patients with post-surgical voiding dysfunction when selecting for urethrolysis.

ABBREVIATIONS

BOO = Bladder outlet obstruction
 B-G = Blaivas-Groutz;
 CI = confidence interval
 pDet = detrusor pressure
 Q_{max} = maximum flow
 UDS = Urodynamics
 VUDS = Video urodynamic study
 VCC = voiding chain cystourethrography

ACKNOWLEDGMENTS

Funding for the statistical analysis in this manuscript was provided by the Department of Urology at Mayo Clinic, Jacksonville, FL, USA

CONFLICT OF INTEREST

None declared.

REFERENCES

1. Akikwala TV, Fleischman N, Nitti VW: Comparison of diagnostic criteria for female bladder outlet obstruction. *J Urol.* 2006; 176: 2093-7.
2. Blaivas JG, Groutz A: Bladder outlet obstruction nomogram for women with lower urinary tract symptomatology. *Neurourol Urodyn.* 2000; 19: 553-64.
3. Barnes AC: The roentgenologic study of urethral sphincter strength in the female. *J Urol.* 1942; 47: 694-701.
4. Nitti VW, Tu LM, Gitlin J: Diagnosing bladder outlet obstruction in women. *J Urol.* 1999; 161: 1535-40.
5. Chassagne S, Bernier PA, Haab F, Roehrborn CG, Reisch JS, Zimmern PE: Proposed cutoff values to define bladder outlet obstruction in women. *Urology.* 1998; 51: 408-11.
6. Lemack GE, Zimmern PE: Pressure flow analysis may aid in identifying women with outflow obstruction. *J Urol.* 2000; 163: 1823-8.
7. Defreitas GA, Zimmern PE, Lemack GE, Shariat SF: Refining diagnosis of anatomic female bladder outlet obstruction: comparison of pressure-flow study parameters in clinically obstructed women with those of normal controls. *Urology.* 2004; 64: 675-9; discussion 679-81.
8. Gomelsky A, Nitti VW, Dmochowski RR: Management of obstructive voiding dysfunction after incontinence surgery: lessons learned. *Urology.* 2003; 62: 391-9.
9. Groutz A, Blaivas JG, Chaikin DC: Bladder outlet obstruction in women: definition and characteristics. *Neurourol Urodyn.* 2000; 19: 213-20.
10. Massey JA, Abrams PH: Obstructed voiding in the female. *Br J Urol.* 1988; 61: 36-9.
11. Bradley CS, Rovner ES: Urodynamically defined stress urinary incontinence and bladder outlet obstruction coexist in women. *J Urol.* 2004; 171: 757-60; discussion 760-1.
12. Scarpero HM, Dmochowski RR, Nitti VW: Repeat urethrolysis after failed urethrolysis for iatrogenic obstruction. *J Urol.* 2003; 169: 1013-6.
13. Lemack GE: Urodynamic assessment of bladder-outlet obstruction in women. *Nat Clin Pract Urol.* 2006; 3: 38-44.
14. Thiel DD, Pettit PD, McClellan WT, Petrou SP: Long-term urinary continence rates after simple sling incision for relief of urinary retention following fascia latapubovaginal slings. *J Urol.* 2005; 174: 1878-81.
15. Carr LK, Webster GD: Voiding dysfunction following incontinence surgery: diagnosis and treatment with retropubic or vaginal urethrolysis. *J Urol.* 1997; 157: 821-3.

16. Greenwald SW, Thornbury JR, Dunn LJ: Cystourethrography as a diagnostic aid in stress incontinence. An evaluation. *Obstet Gynecol.* 1967; 29: 324-7.
17. Stevens W, Smith SP: Roentgenological examination of the female urethra. *J Urol.* 1936; 37: 194-201.
18. Hodgkinson CP: Stress urinary incontinence in the female. *Surg Gynecol Obstet.* 1965; 120: 595-613.
19. Hodgkinson CP: Relationships of the female urethra and bladder in urinary stress incontinence. *Am J Obstet Gynecol.* 1953; 65: 560-73.

Correspondence address:

Dr. Steven P. Petrou
Mayo Clinic
3 East Department of Urology
4500 San Pablo Road
Jacksonville, FL, 32224, USA
Fax: + 1 904 953-2218
E-mail: petrou.steven@mayo.edu