

LAPAROSCOPIC ORCHIECTOMY: EXPERIMENTAL RAT MODEL

MARCELO P. GALESSO, GUSTAVO CUCK, MARCIO R. PAGAN, RONI C. FERNANDES,
MARJO D.C. PEREZ, FLÁVIA C.S. BOTTER

Division of Urology, Irmandade da Santa Casa de Misericórdia de São Paulo, São Paulo, SP, Brazil

ABSTRACT

Studies in animal models have been fundamental to evaluate, refine and practice laparoscopic procedures. Selection of surgical models is primarily based on cost, availability, anatomic and physiologic considerations, housing and anesthetic methods. Large animals, such as pigs and dogs, are preferred to perform experimental laparoscopic procedures. These animals are well accepted by surgeons, because their anatomy is similar to human anatomy, although they are costly and difficult to keep.

The development of small animal models for laparoscopic procedures is essential for basic pathophysiologic and oncologic studies, instrument development and surgical training. Rats appear to be fitting models for laparoscopic research as they are inexpensive, well-studied and widely used in research. Laparoscopic procedures in these animals have been shown to be technically feasible with suitable equipment and instruments.

A standard laparoscopic procedure technique for rats has been developed to perform procedures in all abdominal regions, by using special equipment and instruments as the 4 mm arthroscope or bronchoscope, the 2 mm and 3 mm laparoscopic ports and the 2 mm laparoscopic tissue grasper and scissors.

The present study describes a simple, inexpensive and reproducible technique for laparoscopic orchietomy in a rat model by using the same instruments developed for humans. The present rat model allows the possibility of training a large number of surgeons in laparoscopic procedures, while requiring a minimum amount of logistic and financial efforts.

Key words: laparoscopy; rat; orchietomy; model, animal
Braz J Urol, 28: 143-146, 2002

INTRODUCTION

The development of videolaparoscopy in many surgical specialties has attracted a large number of surgeons. Learning this method for future clinical practice requires intensive training with inert tissues, simulators and experimental surgeries in animals.

Medium and large animals are used in many experimental models using videolaparoscopy to perform physiopathologic studies, to develop instruments and to have surgical training (1-3). Performing these procedures in small animals, with the same equipment used in humans, is also feasible, allowing the familiarization with the material and the comprehen-

sion of the basic techniques. It is inexpensive and safe to initiate training with this method.

The objective of this study is to demonstrate a simple and reproducible technique for videolaparoscopic orchietomy in an original low cost experimental model, to attend a larger number of surgeons interested in videolaparoscopy.

SURGICAL TECHNIQUE

Animals

This study used adult male Wistar rats, weighing between 600 and 650 g. The animals, after being kept in standard laboratory conditions

(temperature between 20 and 24°C, relative humidity between 50 and 60%, under controlled light conditions – 12 hours of light, receiving food and water “ad libitum”), were kept without food and water for 8 hours prior to the surgery.

Equipment and Instruments

To perform this procedure a video system with micro-camera, insufflator, light source, electric scalpel, Veress needle, a 10 mm port, two 5 mm ports, a 0° optic, a suture passthrough device, a 5 mm prehension clamp, a 5 mm dissection clamp and 5 mm scissors are necessary.

Procedure

Anesthetic induction is obtained through intraperitoneal injection of a ketamine hydrochloride solution, 40 mg/Kg, and xilidine-dihydrochloride, 10 mg/Kg. Sedation is controlled by evaluating the reflex under painful stimulus. When necessary, a second dose of the anesthetic is used.

The animal is placed in a dorsal decubitus position, with the 4 limbs fixed to the surgical table. Preoperative depilation of the ventral fascia of the rat is performed using a shearer with blade 40, followed by antiseptics with polyvinyl-pyrrolidone iodine solution.

The procedure consists in performing the pneumoperitoneum with Veress needle right below the xiphoid process, through a 5-mm skin incision. To perform the puncture with the needle, manual traction of the anterior abdominal wall of the rat is necessary, so as to perform it safely, without any lesion to intraperitoneal structures. We proceed to the insufflation of the cavity with CO₂, until reaching the maximum pressure of 5 mmHg, when the needle is removed. The skin is divulsed with hemostat up to approximately 10 mm and the 10-mm trocar is inserted, through which the 0° optic is introduced. Two additional 5-mm lateral incisions are done, around 1.5 cm apart from the first, where the trocar for the dissection and prehension clamps will be introduced. The trocars passage should also be preceded with manual traction of the anterior abdominal wall of the rat.

All trocars should be fixed to the skin with 2-0 cotton thread, to hinder their exaggerated introduction or outlet during clamp maneuvers, avoiding loss of the pneumoperitoneum (Figure).

The spermatic cord of the testicle to be removed is exposed with prehension clamp introduced through the homolateral trocar, followed by its traction. At this moment, the testicular vessels and the vas deferens are visualized with the cord. We proceed the dissection to individualize each structure, following with cauterization and section, which can be made with electrocautery or ultrasonic scalpel, inserted in the cavity through the contralateral trocar. After cord section, traction of the testicle from the scrotum is performed, followed by cauterization and section of the gubernaculum. As an alternative to this surgical time, a suture passthrough device with 2-0 catgut can be introduced through the contralateral trocar. Then the testicle is tractioned

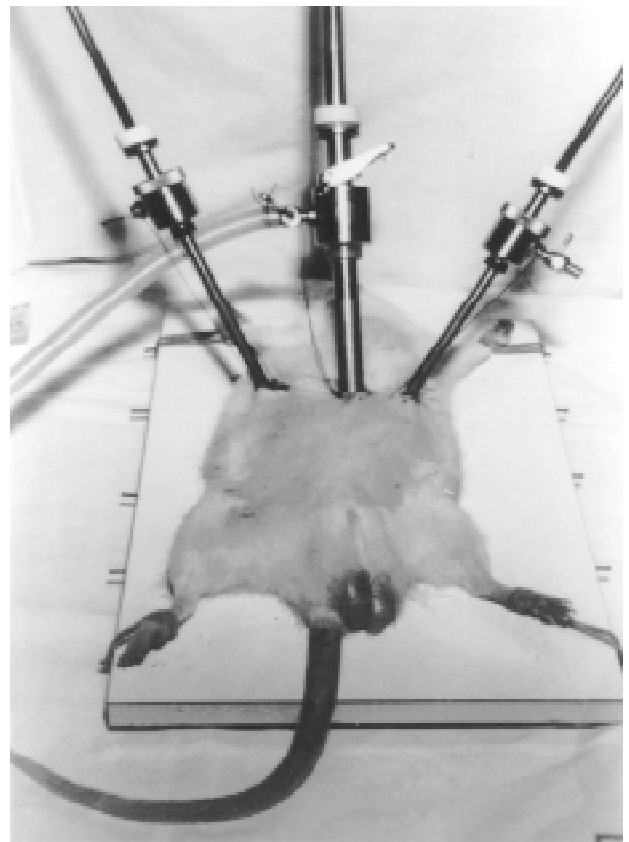


Figure - Anesthetized rat demonstrating the location of the laparoscopic ports.

through its loop with the prehensio clamp inserted through the homolateral trocar. After closing the loop, the gubernaculum is sectionated and, subsequently, the thread. The free testicle is kept in the cavity and the same procedure is performed with the contralateral testicle.

As soon as the bilateral orchiectomy is finished, the 5-mm trocar openings are amplified with hemostat and the testicles are removed from the cavity. The trocar openings are closed with 2-0 cotton thread.

COMMENTS

Videolaparoscopy is becoming the procedure of choice for the diagnosis and treatment of many diseases which were previously performed by laparotomy. The method is attractive for being minimally invasive, reducing postoperative pain, hospital stay and recovery time (2-4).

Learning this method for future clinical practice requires intensive training with inert tissues, simulators and experimental animals.

Traditionally, medium animals, such as dogs and pigs, have been used in experimental videolaparoscopy, for the technical facility provided by their size, anatomic similarity and possibility of using the same instruments used in humans (5). However, their physiology is not very well studied, when compared to other models, and the costs to acquire and maintain them are not despicable (2). Legal restrictions and the public opinion have also made it difficult to use large animals as models in experimental studies (3).

Small animals are also used in videolaparoscopy experimental models. Many techniques have been described in rats (fundoplication, splenectomy, nephrectomy, hepatic resection, herniorrhaphy, colostomy, colectomy and retroperitoneal exploration), as well as their use in studies about immunity, oncology and physiologic effects of the laparoscopy (2-4). Therefore, many endoscopic and microsurgical equipment is necessary for these procedures (arthroscopes, bronchoscopes, trocars and 2 and 3-mm clamps), which can restrict their application (4,5).

When accessible, however, such materials must be used because they increase the working space and allow technical training, such as free suture in small animals, thus developing fine movements, while preserving familiarization and learning of the basic laparoscopy principles.

Videolaparoscopic orchiectomy in rats has proved to be a simple and feasible procedure. In our model, we used the same equipment as in human surgeries, without the need of any sophisticated technology. All animals survived the procedure. Bleeding was despicable. Necropsy, performed 24 hours later, did not show lesions to other intraperitoneal structures. Euthanasia was performed by intracardiac injection of 40 mg/kg thionembutal.

The adequate use of the material described in this experimental model does not significantly limit urologists in the initiation and basic training of laparoscopy.

The use of small animals, besides being more stimulating than the simulators and other inert models, minimize costs, allowing the use of more animals for teaching, training and application in many studies.

REFERENCES

1. Kaouk LH, Gill IS, Meraney AM, Desai MM, Carvalhal EF, Fergany AF et al.: Retroperitoneal minilaparoscopic nephrectomy in the rat model. *Urology*, 56: 1058-1062, 2000.
2. Giuffrida MC, Marquet RL, Kazemier G, Wittich PH, Bouvy ND, Bruining HA et al.: Laparoscopic splenectomy and nephrectomy in a rat model: decription of a new technique. *Surg Endosc*, 11: 491-494, 1997.
3. Gutt, CN; Riemer V, Brier C, Berguer R, Paolucci V: Standardized technique of laparoscopic surgery in the rat. *Dig Surg*, 15:135-139, 1998.
4. Farias EA, Fontes PRO, Rhoden CR, Lucas ML, Leal MLM, Sabedotti M et al.: Acompanhamento de um modelo de indução de cirrose em ratos mediante videolaparoscopia. *Acta Cir Bras*, 15: 163-167, 2000.

5. Sandoval BA, Sulaiman TT, Robinson AV, Stellato TA: Laparoscopic surgery in a small animal model: a simplified technique of retro-peritoneal dissection in the rat. *Surg Endosc*, 10: 925-927, 1996.

Received: September 17, 2001

Accepted after revision: February 8, 2002

Correspondence address:

Dr. Roni de Carvalho Fernandes
Rua Cotoxo, 987 / 94
São Paulo, SP, 05021-001, Brazil
E-mail: roni.fernandes@uol.com.br