

Percutaneous Intervention of Large Bladder Calculi in Neuropathic Voiding Dysfunction

Chad P. Hubsher, Joseph Costa

Division of Urology, University of Florida College of Medicine, Jacksonville, Florida

ABSTRACT

Purpose: To report our results and rationale for treating large bladder calculi in patients with neuropathic voiding dysfunction (NVD) using percutaneous cystolitholapaxy.

Materials and Methods: Ten patients with a previously diagnosed NVD presenting with a large stone burden were identified from our department database and a retrospective review of case notes and imaging was performed.

Results: Percutaneous access to remove bladder stones (range 8x7 to 3x2 cm) had a mean surgery length of 150 min and blood loss of 23 mL. Six of the seven patients treated percutaneously were discharged on the day of surgery and suffered no complications, while one patient experienced poor suprapubic tube drainage and required overnight admission with discharge the following day. Transurethral removal of stone burden (range 4x4 to 4x3 cm) had a mean surgery length of 111 min and blood loss of 8 mL. Each of these three patients were under our care for less than 23 hours, and one patient required a second attempt to remove 1x0.5 cm of stone fragments. There was no statistical difference between mean operative times and estimated blood loss, $p = 0.5064$ and $p = 0.0944$ respectively, for the two treatment methods.

Conclusion: In this small series, percutaneous cystolitholapaxy was a safe, effective, and often preferred minimally invasive option for removal of large calculi in patients with NVD. We suggest possible guidelines for best endoscopic approach in this population, although a larger and prospectively randomized series will be ideal for definitive conclusions.

Key words: *urinary bladder; calculi; neurogenic; laparoscopy; lithotripsy*

Int Braz J Urol. 2011; 37: 636-641

INTRODUCTION

Bladder stones are a well-recognized late complication of NVD, including those who have undergone prior bowel to bladder reconstruction. Reported risk factors for developing bladder stones include patient age, type of augmented diversion, immobilization contributing to hypercalciuria and oxalate calcium stone formation, and infected urine (1-3). Infection of the urine may be secondary to urinary stasis with incomplete emptying, repeated instrumentation or catheterization, and foreign bodies, such as mucous, hair, or amorphous sediment (4,5).

Neuropathic conditions causing decreased patient sensitivity often permit calculi to develop without complaint until the burden becomes numerous,

large, and painful. Prior bladder augmentation and a large stone burden can cause the removal of calculi to be more challenging. Comparison of approaches to remove bladder stones of a small size have indicated percutaneous and endoscopic techniques to be more advantageous than open cystolithotomy in terms of shorter hospitalization periods, less post-operative morbidity, and minimal damage to blood flow of intraperitoneal tissue (6).

However, current literature describing the optimal approach to large bladder stones in patients with NVD is lacking. We hypothesize that in this patient population, a minimally invasive technique would be beneficial as it reduces risk to the patient's internal anatomy, which is often distorted due to previous surgeries, manipulation, or their NVD condition. When taking into consideration each patient's

unique complexities, as well as the various sizes of calculi, the most favorable endoscopic approach in patients with NVD has yet to be explored. Thus, with the goal of reducing morbidity, we report our results and rationale for using percutaneous cystolitholapaxy as an intermediate step for stones too large or inappropriate for transurethral management, and as an attempt to avoid open surgical removal in a complex NVD population with large vesical calculi.

MATERIALS AND METHODS

Ten patients (four male and six female) with previously diagnosed NVD who also presented with bladder stones between 2005 and 2009 were identified from our departmental database, and case notes and available images were reviewed retrospectively. We assessed the neuropathic history, prior bladder surgeries and complications, and urodynamic findings of each patient. We then compared the stone burden, surgical procedure and any encountered complications to remove the calculi, length and details of surgery, length of hospital stay, and recurrence. The ten patients were organized retrospectively into two groups based on the procedure performed.

Group 1 consisted of patients that had undergone cystolitholapaxy through a percutaneous suprapubic approach. In this group, percutaneous suprapubic access was gained either through an old suprapubic tract scar, at a new site if judged safe based on exam and cystoscopy, or under CT guidance when deemed too high of a risk to perform otherwise. The tract was dilated with standard balloon dilatation routinely used for percutaneous nephrolithotomy procedures, and a 30 french Amplatz sheath was left in situ for direct access to the bladder during the procedure. Depending on the stone characteristics; pneumatic, ultrasonic, and holmium laser tools were used to fragment and then irrigate the calculi under direct visualization via rigid and flexible nephroscopy. After clearance of all calculi, the instruments were removed and a 16 french suprapubic catheter was left to gravity drainage. The suprapubic tube was removed in the office at post-operative follow-up if it was not to be used for continued management of the patient's NVD.

Group 2 consisted of patients that had undergone cystolitholapaxy via their native urethra. In these patients a holmium laser was utilized to fragment the stones via flexible and rigid Cystoscopy with 16-24 french instruments. The fragments were then irrigated and evacuated through the urethral sheath. In patients with an augmented bladder and catheterizable stoma, the catheterizable limb was never used as a channel to remove calculi. Patients with smaller urethral outlets, prior hypercontinent sling, or prior bladder neck closure, were all approached percutaneously. The rationale to utilize a suprapubic site versus the urethra as the conduit for stone extraction was then analyzed.

RESULTS

Of the ten patients who presented with NVD and concurrent bladder calculi, the NVD diagnosis was attributed to spina bifida in five patients, traumatic brain or spinal cord injury in three patients, congenital bladder exstrophy in one patient, and chronic urinary retention in one patient with a congenital connective tissue disorder. Five of the ten patients had also undergone previous enterocystoplasty bladder augmentation with formation of a catheterizable stoma, including the patient with congenital bladder exstrophy (Table-1). At the time of stone removal the mean age of the ten patients was 31 years (range 19-57).

Percutaneous stone extraction was performed on a total of seven patients (70%), with stone size ranging from 8x7 to 3x2 cm. Three of the patients, with stone burdens of 4x4, 4x3, and 3x2 cm, had a patent urethra and a pre-existing suprapubic tube in place prior to discovery of the bladder calculi. The patient with congenital bladder exstrophy had an 8x7 cm stone burden and a history of multiple bladder surgeries resulting in an enterocystoplasty bladder augmentation and closure of the bladder neck. The three other patients, two of which had previous enterocystoplasty bladder augmentations, all had patent urethras, no pre-existing suprapubic tubes, and stone burdens of 6x2, 6x5, and 7x7 cm. Six of the seven patients treated percutaneously were discharged on the day of surgery and suffered no complications, while one patient experienced poor suprapubic tube drainage and required an overnight

Percutaneous Intervention of Large Bladder Calculi

admission. No complications were observed after discharge from the hospital. The average length of surgery to remove large bladder calculi via cystolitholapaxy through a percutaneous suprapubic approach was 150 minutes (range 35 - 260 min.) with a mean estimated blood loss of 23 mL. No patient

Group 2 consisted of three patients (30%), none of which had a pre-existing suprapubic tube in place. One patient had a 4x3 cm stone burden with no previous bladder surgeries, while the other two patients both each had a 4x4 cm stone burden and an augmented bladder and catheterizable stoma. One

Table 1 - Patient characteristics.

Pt #	Neurogenic History	SPT	Size (cm)	Past Bladder Surgery	Patent Urethra	Approach
1	Bladder Extrophy	Yes	8x7	Enterocystoplasty bladder augmentation with subsequent revision, bladder neck closure, ureterectomy	No	Percutaneous
2	Spina Bifida	No	7x7	Enterocystoplasty bladder augmentation with catheterizable stoma	Yes	Percutaneous
3	Traumatic SCI	No	6x5	No	Yes	Percutaneous
4	Spina Bifida	No	6x2	Enterocystoplasty bladder augmentation, bladder neck reconstruction with hypercontinent sling	Yes	Percutaneous
5	Traumatic SCI	Yes	4x4	No	Yes	Percutaneous
6	Spina Bifida	No	4x4	Enterocystoplasty bladder augmentation with catheterizable stoma	Yes	Urethra
7	Spina Bifida	No	4x4	Enterocystoplasty bladder augmentation with catheterizable stoma	Yes	Urethra
7 (2)	Spina Bifida	No	1x0.5	Enterocystoplasty bladder augmentation with catheterizable stoma	Yes	Urethra
8	Spina Bifida	Yes	4x3	No	Yes	Percutaneous
9	Traumatic SCI	No	4x3	No	Yes	Urethra
10	Chronic UR	Yes	3x2	No	Yes	Percutaneous

cm = centimeters, Pt = patient, SCI = spinal cord injury, SPT = suprapubic tube, UR = urinary retention

in this group required a second attempt to remove remaining fragments, nor did any patient experience bowel injury while creating the percutaneous access or at anytime throughout the procedure.

of these last patients required a second attempt two weeks after the initial process to extract remaining fragmented stones, totaling 1x0.5 cm, which could not be removed during the first procedure. Each of

these patients was under our care for less than 23 hours. Patients that had undergone cystolitholapaxy via their native urethra had an average length of surgery, including second attempts, of 111 minutes (range 38-250 min.), and a mean estimated blood loss of 8 mL. After the procedure, there was no reported increase in incontinence through the urethra, and no urethral strictures or other complications possibly due to the surgery were observed in this patient population. Using a two-sample t-test, statistical comparison of mean operative times and blood loss between a percutaneous and transurethral approach yielded no significant difference, $p = 0.5064$ and $p = 0.0944$ respectively.

DISCUSSION

Patients with NVD are at a higher risk of calculus formation. Those who have undergone prior enterocystoplasty have reported incidences of bladder calculi as high as 50% (7). The etiology of bladder stone formation appears to be multifactorial, with urinary stasis likely the most significant factor. We stratified our patients with bladder calculi in terms of stone burden, history of lower

urinary tract surgeries, and presence of a native urethra, suprapubic tube, and catheterizable stoma. Our goal in stratification is completing stone removal in a single operative procedure and with the least amount of operative time, while minimizing morbidity and returning the patient to baseline function as rapidly as possible.

Our retrospective review of this small case series allows recommendations to be generated regarding percutaneous versus native urethral approach in NVD patients with a large stone burden. In this patient population, the presence of a pre-existing suprapubic tube provides an easily accessible tract that could be utilized to gain access percutaneously, minimizing the inherent risks associated with initial percutaneous access to the bladder. If there is no suprapubic tube present, it is then important to consider the size of the stone when determining if a percutaneous procedure is appropriate. Retrospective analysis of our data indicates that with a stone burden greater than 4 cm, a percutaneous approach was the procedure of choice (Figure-1). When choosing the suprapubic site, prior imaging, physical exam findings, and cystoscopy were utilized to minimize risk of injury to bowel or major vascular structures. It is

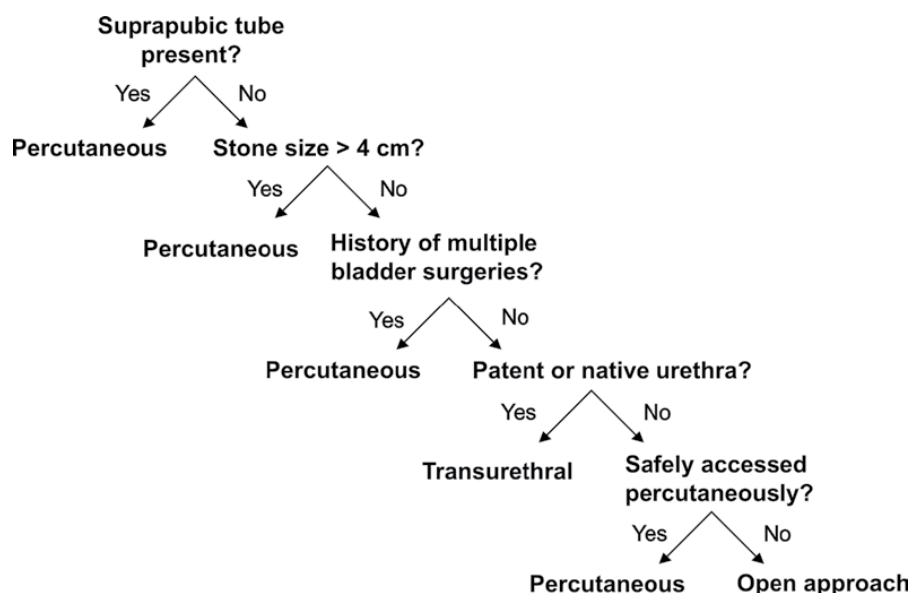


Figure 1 - Recommendations for percutaneous treatment of large bladder calculi in patients with neuropathic voiding dysfunction.

recommended that CT guided access be considered in patients who are at high risk for bowel injury, such as those with prior enterocystoplasty and/or multiple prior open surgical procedures. In our patient population, CT scan was used to obtain access in one patient who was born with bladder exstrophy and had a history of multiple prior surgeries, including bladder closure with pubic symphysis reapproximation and placement of a colonic reservoir that was subsequently revised.

A transurethral approach to remove bladder calculi was performed on three patients with stone burdens of 4x3, 4x4, and 4x4 cm. One of the three required a second “look”, or follow-up surgical procedure, to extract remaining fragments. None of the patients in this group had a pre-existing suprapubic tube, and all had a patent urethra.

In our experience, patients with a patent and non-reconstructed native urethra/bladder neck who presented with calculi less than 4 cm were well managed with a transurethral approach. However, those with a stone burden greater than 4 cm in a single dimension and/or coexistence of the prior lower urinary tract surgeries discussed above were chosen to be managed percutaneously. This 4 cm cutoff was initially an arbitrarily assigned volume based on the author’s experience that larger stone volumes would potentially take excessive operative time if performed transurethrally. Although the average length of surgery was greater in the percutaneous group (150 min.) compared to the transurethral group (111 min.), the difference in operative times was not statistically different ($p = 0.5064$). Similarly, the observed difference in the mean estimated blood loss, 23 mL for group 1 and 8 mL for group 2, is also determined to not be statistically significant ($p = 0.0944$). Furthermore, the lack of complications and postoperative morbidity observed in both groups continues to demonstrate safety for either approach.

Patients with multiple prior lower urinary tract procedures and a large stone burden, present with a potentially very complex scenario which must give the surgeon reason to pause and consider the best approach to take. When initially presented with a complex NVD patient, the decision to undergo a transurethral versus percutaneous approach was based on the amount of time it would likely take

to fragment the stone. Our 10 patient sample series demonstrates that it is effective and safe to utilize a percutaneous approach on patients with stones greater than 4 cm. However, as we never attempted to utilize a transurethral approach on stones of this size, we cannot conclude that stones greater than 4 cm cannot also be treated transurethrally.

Initially, we also made the decision to attempt a minimally invasive approach instead of an open procedure for complicated NVD patients with large vesical calculi. This was based on the work of Docimo et al., who compared open and percutaneous cystolithotomy and reported less postoperative morbidity and similar stone recurrence rates between the two groups (6). We observed similar findings as six (86%) of our patients in the percutaneous approach group had a hospital stay of less than 23 hours and only 1 (14%) patient required overnight admission. Open surgery has the inherent risks of extended hospitalization, prolonged catheterization, and an increased risk of infection (8). Although not compared directly, the lack of complications and morbidity that we observed with the percutaneous approach leads us to believe that percutaneous intervention for patients with NVD and large bladder calculi is an acceptable alternative to open cystolithotomy. Percutaneous intervention avoids urethral manipulation and consequently stricture, and the large Amplatz sheath allows larger fragment removal as well as improved visibility by superior irrigation, thus leading us to believe that it is a lower risk procedure in this specific patient population (9-11). Nonetheless, further investigation is warranted to directly compare percutaneous and open procedures in patients with NVD and large vesical calculi.

CONCLUSIONS

In this small series, percutaneous cystolitholapaxy is a safe and under certain circumstances, a more beneficial alternative to a transurethral approach or perhaps even open cystolithotomy in patients with NVD and large bladder calculi. Ret-

rospective analysis of our experience demonstrates that percutaneous cystolitholapaxy was a safe and effective method of choice in patients with a pre-existing suprapubic tube, stone size greater than 4 cm in any single dimension, a history of prior bladder surgery, or in the absence of a patent urethra. We suggest possible guidelines for utilizing a percutaneous approach in this population in place of an open or transurethral procedure, although a larger and prospectively randomized series will be ideal for definitive conclusions.

ABBREVIATIONS

cm = centimeter
CT = computed tomography
min = minute
mL = milliliter
NVD = neuropathic voiding dysfunction
Pt = patient
SCI = spinal cord injury
SPT = suprapubic tube
UR = urinary retention

CONFLICT OF INTEREST

None declared.

REFERENCES

1. Blyth B, Ewalt DH, Duckett JW, Snyder HM 3rd: Lithogenic properties of enterocystoplasty. *J Urol.* 1992; 148: 575-7; discussion 578-9.
2. Kronner KM, Casale AJ, Cain MP, Zerlin MJ, Keating MA, Rink R: Bladder calculi in the pediatric augmented bladder. *J Urol.* 1998; 160: 1096-8; discussion 1103.
3. Naftchi NE, Viau AT, Sell GH, Lowman EW: Mineral metabolism in spinal cord injury. *Arch Phys Med Rehabil.* 1980; 61: 139-42.
4. Park YI, Linsenmeyer TA: A method to minimize indwelling catheter calcification and bladder stones in individuals with spinal cord injury. *J Spinal Cord Med.* 2001; 24: 105-8.
5. Derry P, Nuseibeh I: Vesical calculi formed over a hair nidus. *Br J Urol.* 1997; 80: 965.
6. Docimo SG, Orth CR, Schulam PG: Percutaneous cystolithotomy after augmentation cystoplasty: comparison with open procedures. *Tech Urol.* 1998; 4: 43-5.
7. Palmer LS, Franco I, Kogan SJ, Reda E, Gill B, Levitt SB: Urolithiasis in children following augmentation cystoplasty. *J Urol.* 1993; 150: 726-9.
8. Maheshwari PN, Oswal AT, Bansal M: Percutaneous cystolithotomy for vesical calculi: a better approach. *Tech Urol.* 1999; 5: 40-2.
9. Ikari O, Netto NR Jr, D'Ancona CA, Palma PC: Percutaneous treatment of bladder stones. *J Urol.* 1993; 149: 1499-500.
10. Franzoni DF, Decter RM: Percutaneous vesicolithotomy: an alternative to open bladder surgery in patients with an impassable or surgically ablated urethra. *J Urol.* 1999; 162: 777-8.
11. Aron M, Agarwal MS, Goel A: Comparison of percutaneous with transurethral cystolithotripsy in patients with large prostates and large vesical calculi undergoing simultaneous transurethral prostatectomy. *BJU Int.* 2003; 91: 293-5.

*Submitted for publication:
 April 05, 2010*

*Accepted after revision:
 January 05, 2011*

Correspondence address:

Dr. Joseph Costa
 Division of Urology
 UF College of Medicine, Jacksonville
 653 West 8th Street
 Jacksonville, FL 32209
 Fax: + 1 904 244-7422
 E-mail: joseph.costa@jax.ufl.edu