



# Tubularized incised plate urethroplasty for hypospadias reoperation: a review and meta-analysis

Seyed A. Mousavi<sup>1</sup>, Mohsen Aarabi<sup>2</sup>

<sup>1</sup>Department of Pediatric Surgery, Faculty of Medicine, Mazandaran University of Medical Sciences, Sari, Iran; <sup>2</sup>Health Sciences Research Center, Mazandaran University of Medical Sciences, Sari, Iran

## ABSTRACT

**Purpose:** Tubularized Incised Plate (TIP) urethroplasty is a technique for urethral reconstruction of hypospadias although there are some controversies for its use in recurrent cases. The aim of this study was to review the results of TIP technique in various studies and the usage of different flaps for covering the repair site.

**Material and Methods:** Extensive Search was performed for articles published between 1994 and 2013 in common electronic databases. The overall TIP complication rates were estimated by a fixed effects model meta-analysis.

**Results:** 17 articles of hypospadias repair using the TIP method were reviewed. All studies performed surgery and repair on the basis of the Snodgrass's method; however, some introduced modifications to the method. The prevalence of complications in repeated TIP surgery was 11.1 to 33.3% and the most prevalent complication in different studies was fistula. Based on the meta-analysis, the overall estimation of complications was 21.8 % (95% CI: 18.3 to 25.5).

**Conclusion:** Most studies performed the incision of the urethral plate to create a supportive coverage upon neourethra, and confirmed its success. We recommend further investigation on using different flaps in well-designed randomized controlled trials to choose the best surgical method for repairing recurrent hypospadias.

## ARTICLE INFO

### Key words:

Hypospadias; Reoperation; Technique; Surgical

*Int Braz J Urol.* 2014; 40: 588-95

Submitted for publication:  
September 30, 2013

Accepted after revision:  
December 22, 2013

## INTRODUCTION

Hypospadias are one of the most common inherent genital anomalies in boys. A common complication of several correcting techniques for hypospadias is fistula. The dehiscence of the repaired hypospadias is less prevalent than fistula, which worries surgeons, with both complications increasing in cripple hypospadias (recurrent cases) (1).

Warren Snodgrass introduced Tubularized Incised Plate (TIP) urethroplasty in 1994 with the least complications. It is performed by a longitudinal cut on the urethral plate with tubularization and placing a flap on it. The most crucial part of this repair

method is creating a relaxing incision at the bottom of the urethral plate and using a dartos flap as a supportive cover on the neourethra (2, 3). Although this method is employed for distal hypospadias, its success for proximal cases has been shown in several published articles (4).

TIP technique is preferred by many surgeons around the globe. However, there are some controversies for its use in recurrent hypospadias and whether it can be used in this situation. Other important arguments include finding a suitable tissue for covering the repair site, in the case of having no adequate prepuce, and the contraindication of previous TIP for deciding to use the TIP technique again.

The aim of this study was to review the complications of TIP method in different articles and the experience of other surgeons in the usage of flaps to cover the repair site. We also estimated complication rates by meta-analysis.

## MATERIALS AND METHODS

English language databases including PubMed and Google Scholar were searched for articles published since the introduction of the TIP technique (Jan 1994) until January 2013. Keywords included in the search strategy were hypospadias, reoperation, urethroplasty and TIP complications.

Inclusion criteria were surgical repairs (proximal, middle, and distal) by the TIP method of hypospadias of patients of any age. Titles and abstracts of papers were checked and all identified studies from the searches were assessed for eligibility. Studies on circumcised patients with hypospadias who haven't enough prepuces for repair were also included. Articles of subjects with glandular type or case reports urethroplasty with less than 5 patients or animal studies were excluded from this review. References of the included papers were also searched for finding the relevant articles.

Included papers were analyzed carefully and detailed information regarding the year of publication, first author, study location, total sample size, mean age, number of surgeries and TIP surgery techniques were collected. The proportion of patients with different complications and variety of flaps were considered as main endpoints of interest. The severity of complications was assumed similar.

Data analysis was carried out by the Stat Direct software. The heterogeneity was evaluated using the  $I^2$  and Cochrane Qstatistics (with significance level of  $P$ -value $<0.1$ ). In the presence of homogeneity, the fixed effects model was used to estimate the overall prevalence of complications.

## RESULTS

129 papers of hypospadias repair using the TIP method were found. After excluding papers by the exclusion criteria, full texts of 17 articles of repeated surgery by the TIP technique were included in this study. An overall view of included pa-

pers and their details (time, type of hypospadias, number of surgery and complications) are presented in Table-1. In total, 514 patients with different types of hypospadias, aged 7 to 34 months, were operated by the TIP method. The minimum and maximum numbers of surgeries were 1 and 5 times, respectively.

In all studies, surgery and repair were performed based on the Snodgrass's method (5); however some studies introduced modifications to the method (Table-2). For instance, Nguyen et al (6) used a 'ventral dartos flap' on 18 out of 27 patients. Occurrence of fistula as a complication was reported in 6% of this group. In the other group, the adjacent tissue was used and the prevalence of fistula was 16%. Gurdal et al (7) reported 90% success of using the 'tunica vaginalis reinforcement flap' on 9 patients. In another study, Hayashi et al (8) used an alternative flap such as the 'periurethral tissue' and the 'de-epithelialized meatal-based flip-flap' with a 100% success rate on their 5 patients. The neourethra was covered in the study by Shanberg et al. (9) by creating a 'rectangular flap' and making two parallel incisions at the lateral side of the shaft of penis leading to 85% success rate in 13 patients.

In another study carried out on 133 recurrent hypospadias patients, 3 surgical methods were employed for repair. The TIP method, inlay flap and two-stage buccal graft had an overall 74% success rate with 19, 15 and 38% complication proportions respectively. The authors suggested that these methods are useful for repairing without using any skin flap (10). For treating severe scars, Ye et al (11) suggested urethral plate repair by the dorsal inlay buccal mucosal graft. This was followed by the urethral tubularization and covering by the subcutaneous dartos. This modification had 85% success rate on 53 patients. In Saleh et al (12) serious complications occurred in 5 (17%) patients, consisting mostly of fistulas. Among 15 of these cases in which dartos was used alone as a barrier layer, fistulas occurred in 3 (20%) patients. However, the fistula frequency reached zero when a tunica vaginalis flap was added to the dorsal flap.

The proportion of complications in the repeated TIP surgery was between 11.1 and 33.3% with an average of 20.7% (Figure-1). Based on our

**Table 1 - Characteristics of studies reporting secondary (redo) hypospadias operation.**

Author/Date	N° of patients	Mean age (y)	Mean N of operation	Type	Overall Complication rate (%)	Fistula %	Meatal Stenosis %	Urethral stricture %	Dehiscence %
Luo et al - 1999 <sup>6</sup>	6	4.6	1	D-M	(33.3)	16.6	16.6*	None	None
Yang et al - 2001 <sup>29</sup>	25	11.4	2.5	D-M-P	-	28	52	8	None
Hayashi et al – 2001 <sup>8</sup>	5	7.4	1	D	(20)	20	None	None	None
Shanberg et al - 2001 <sup>9</sup>	13	7.5	2.5	D-M-P	(15.3)	7.6	7.6	None	7.6
Snodgrass et al – 2002 <sup>5</sup>	15	4.2	1	D-M	(20)	13.5	None	None	6.6
Gürdalet al – 2003 <sup>7</sup>	9	-	-	D	(11.1)	11.1	None	None	None
El-sherbiny et al – 2004 <sup>21</sup>	30	7	-	D-M-P	(20)	9	5	None	3
Nguyen et al – 2004 <sup>6</sup>	31	-	1.1	D-M-P	(23)	Mostly	-	-	9.6
Cakan et al - 2005 <sup>17</sup>	37	4.1	4.1	D-M-P	(21.6)	10.8	2.7	2.7	5.4
Ziada et al – 2006 <sup>15</sup>	30	4.3	1.6	D-M-P	(23)	20	16.6	None	None
Akal et al - 2006 <sup>30</sup>	18	11.2	1.2	D-M	(22.2)	16.6	5.5	None	5.5
Eliçevik et al - 2007 <sup>28</sup>	100	4.5	-	D-M-P	(26)	18	5	1	2
Saleh et al - 2007 <sup>12</sup>	30	4	1.2	D-M-P	(16.6)	10	6.6	None	None
Ye et al - 2008 <sup>11</sup>	53	11.6	2.1	D-M-P	(15.1)	9.4	None	5.7	None
Mousavi et al - 2008 <sup>20</sup>	17	4.6	1.3	D-M-P	(23.5)	5.8	17.6	None	5.8
Snodgrass et al - 2009 <sup>10</sup>	69	-	1.1	D-M-P	(19)	Mostly	-	-	-
Gozar et al - 2010 <sup>16</sup>	26	5.5	-	D-M-P	(23)	15.2	3.8	-	5.5
Total	514	6.2	1.6		(20.7)	14.1	9.2	1.2	3.1

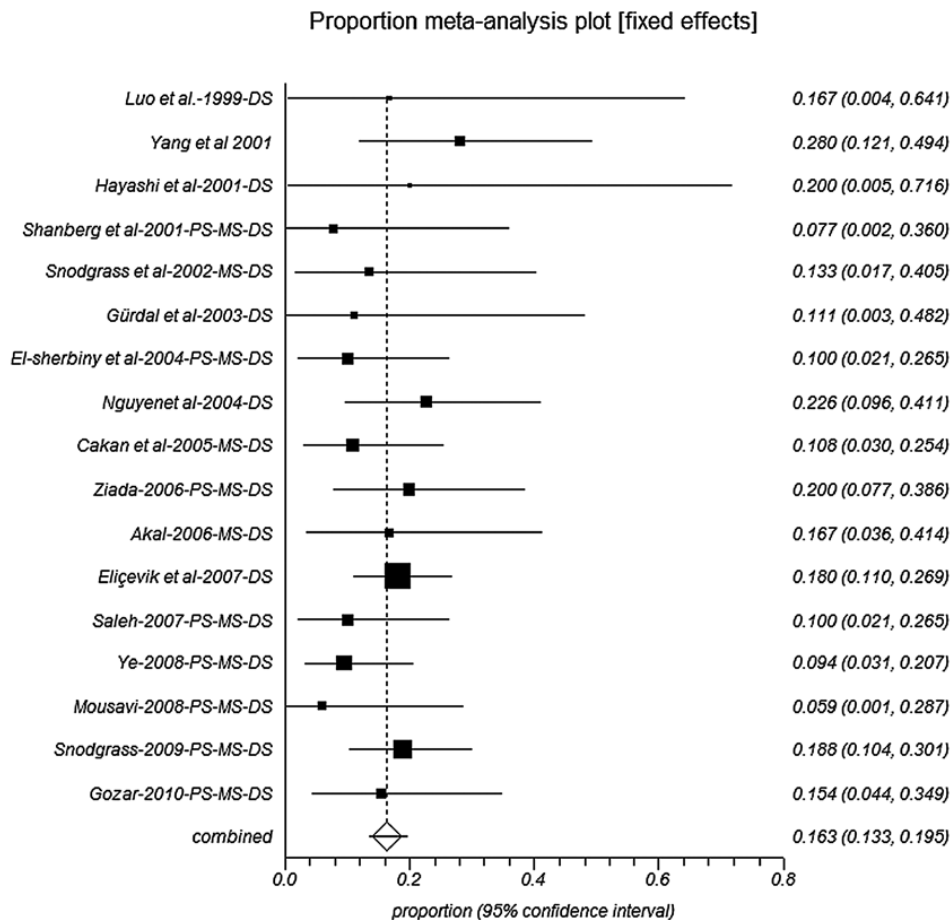
\*Subcoronal hypospadias was included in the distal group

P: Proximal shaft; M: Mid shaft; D: Distal shaft

**Table 2 - Technical modifications for the TIP procedure in patients with secondary (redo) hypospadias.**

First Author	Flap modification	Year
Hayashi et al <sup>8</sup>	periurethral tissue, de-epithelialized meatal-based flip-flap, scrotal dartos flap	2001
Shanberg et al <sup>9</sup>	rectangular flap	2001
Gurdal et al <sup>7</sup>	tunica vaginalis reinforcement flap	2003
Nguen et al <sup>6</sup>	ventral dartos flap, adjacent tissue	2004
Saleh et al <sup>12</sup>	dorsal dartos plus tunica vaginalis flap	2007
Ye et al <sup>11</sup>	dorsal inlay buccal mucosal graft	2008
Snodgrass et al <sup>10</sup>	dorsal dartos flap, ventral dartos flap, adjacent dartos tissue	2009

**Figure 1 - Forest plot of overall complications of 18 secondary (redo) hypospadias operation studies (PS: Proximal shaft; MS: Mid shaft; DS: Distal shaft).**



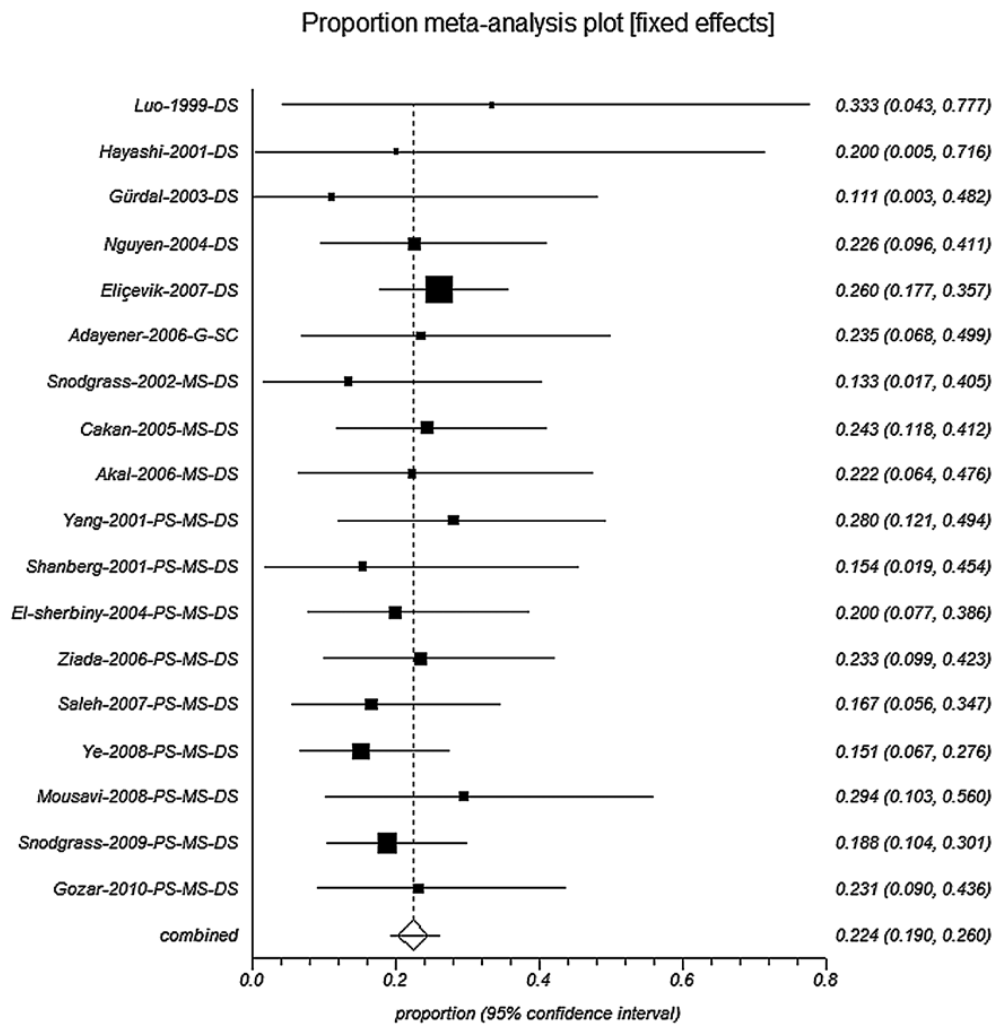
meta-analysis, the overall estimation of complications was 21.8 % (95% CI: 18.3 to 25.5). No heterogeneity was detected between included studies in this meta-analysis, Cochran Q = 4.6 (df = 17), P = 0.996, I<sup>2</sup> = 0%. The most prevalent complication in different studies was fistula with an overall estimate of 16.3% (95% CI: 13.3 to 19.5) (Figure-2).

**DISCUSSION**

This meta-analysis reveals that several modified TIP techniques have been reported in hypospadias patients of different age groups. Indeed,

arguments still exist against utilizing TIP method for patients with recurrent hypospadias (13, 14). There is a belief that penile tissues in younger children have a better chance for the success of repair. Ziada et al. (15) reported a relationship between lower age and more success rate of secondary surgical repairs of hypospadias in a study on 61 patients. Gozar et al (16) described 92.5% success rate in patients younger than 3 years in contrast to the 57% success of pre-pubertal patients. Moreover, Cakan and his coworkers (17) concluded that better results can be achieved in patients below the 5<sup>th</sup> year of their life.

**Figure 2 - Forest plot of Fistula as a complication in 17secondary (redo) hypospadias operation studies, (Cochran Q = 10.4 (df = 16), P = 0.848, I<sup>2</sup> = 0%).**



### The TIP technique in circumcised patients

It is recommended that patients with hypospadias should not be circumcised because of the superiority of the prepuce tissue covering the neourethra. However, in glandular cases this tissue is not required. For repair in severe cases, the dorsal dartos flap is an appropriate tissue to cover the neourethra. The main advantage of these cases is that their U.P. is intact and the periurethral tissue can be used as a supportive flap (18). Pieretti and colleagues (19) reported a high success rate for employing the TIP technique on 48 circumcised patients. This high success rate was reported by other surgeons as well (17, 20).

### Flap types and TIP reoperation

The most important difficulty in patients who have previously undergone unsuccessful repair of hypospadias was the lack of foreskin and adequate tissue for the neourethral coverage. In primary cases, the dorsal dartos flap from the prepuce can be used, but if the tissue was previously removed, the surgeon would use other tissues for support (Table-2). Such cases could be categorized in three groups; ventral dartos flap, dorsal dartos flap and adjacent dartos tissue (5). Surgeons seem to be more willing to use the dartos tissue, especially the dorsal type in the case of lack of prepuce. Also, if possible they prefer to use an additional flap such as the tunica vaginalis for its reinforcement. However, El-Sherbiny et al (21) emphasized on its use in the proximal hypospadias cases.

It should be noted that despite providing an appropriate flap, the meatus location has a great role on the complication rate. Gozar and coworkers (16) reported that success rate in the re-operation of proximal hypospadias cases is 60% while in distal cases it is about 89%. Subramaniam et al (22) reviewed the techniques for distal hypospadias repair and concluded that most surgeons prefer this technique. However, this method, which results in complication in about 33% of cases, has not been yet accepted for the proximal hypospadias. As with most surgical techniques, numerous studies indicated that citation of primary results is hasty for clear conclusion, because the

number of side effects declined significantly when surgeons are more experienced (16, 17 23-25).

### Scar and complications

It seems that with the increase of the number of surgeries and related scars, tissue perfusion decreases and the prevalence of side effects increase. Cakan and colleagues (17) studied 37 patients with distal and middle hypospadias. They reported a 82.6% success rate in patients with one previous surgery as opposed to the 28.6% in patients with two previous surgeries similar to other studies (16, 26). Nevertheless, El-Sherbiny et al. (21) 4-year study on the rate of complications of the TIP technique with 133 patients concluded a similarity between primary and secondary repairs.

Snodgrass et al (27) reported severe scar and ventral curvature as the only contraindications for the TIP technique in re-operation. Similarly, Nguen et al (16) and Eliçevik et al (28) emphasized that this technique is the best for repair of the recurrent hypospadias if the urethral plate has not been excised (6, 28). There is also the remarkable question of using the TIP technique on cases where scars on the urethral plate occurred after the primary TIP urethroplasty. Snodgrass believed that using the TIP technique had no contraindications in contrast to Nguen et al (6) and Cakan et al (17), who believed that the complications are not related to the previous incision on the urethral plate. In contrast, Eliçevik et al (20) concluded that a 'redo third redo' operation should be avoided due to the increased rate of complications by the TIP's secondary repair.

Yang and coworkers (29) studied complications in patients without U.P. manipulation and reported that there were no complications in this group compared to the 41.2% occurrence of complications, mostly fistula, in patients with a history of the TIP urethroplasty.

### CONCLUSIONS

The number of published articles in performing the TIP technique for the treatment of secondary hypospadias are limited in comparison to papers from primary cases and because of the

varied age range of patients, the results of surgeries can be affected. Most studies were established on the incision of the urethral plate and creating a supportive coverage upon the neourethra, and confirmed its success. Consequently, the use of different flap types is recommended to be studied in well-designed randomized controlled trials to choose the best surgical method for repair of recurrent hypospadias.

## CONFLICT OF INTEREST

None declared.

## REFERENCES

- Borer JG, Retik AB. Hypospadias. In: Campbell-Walsh Urology. 3703–3710, 9th ed. Philadelphia: Saunders; 2007.
- Snodgrass W: Tubularized, incised plate urethroplasty for distal hypospadias. *J Urol.* 1994; 151: 464-5.
- Snodgrass WT, Bush N, Cost N: Tubularized incised plate hypospadias repair for distal hypospadias. *J Pediatr Urol.* 2010; 6: 408-13.
- Snodgrass W, Koyle M, Manzoni G, Hurwitz R, Caldameo A, Ehrlich R: Tubularized incised plate hypospadias repair for proximal hypospadias. *J Urol.* 1998; 159: 2129-31.
- Snodgrass WT, Lorenzo A: Tubularized incised-plate urethroplasty for hypospadias reoperation. *BJU Int.* 2002; 89: 98-100.
- Nguyen MT, Snodgrass WT: Tubularized incised plate hypospadias reoperation. *J Urol.* 2004; 171: 2404-6; discussion 2406.
- Gürdal M, Karaman MI, Kanberoglu H, Kireççi S: Tunica vaginalis reinforcement flap in reoperative Snodgrass procedure. *Pediatr Surg Int.* 2003; 19: 649-51.
- Hayashi Y, Kojima Y, Mizuno K, Nakane A, Tozawa K, Sasaki S, et al.: Tubularized incised-plate urethroplasty for secondary hypospadias surgery. *Int J Urol.* 2001; 8: 444-8.
- Shanberg AM, Sanderson K, Duel B: Re-operative hypospadias repair using the Snodgrass incised plate urethroplasty. *BJU Int.* 2001; 87: 544-7.
- Snodgrass WT, Bush N, Cost N: Algorithm for comprehensive approach to hypospadias reoperation using 3 techniques. *J Urol.* 2009; 182: 2885-91.
- Ye WJ, Ping P, Liu YD, Li Z, Huang YR: Single stage dorsal inlay buccal mucosal graft with tubularized incised urethral plate technique for hypospadias reoperations. *Asian J Androl.* 2008; 10: 682-6.
- Saleh AM: Tubularized incised plate urethroplasty (tip) after failed hypospadias repair. *Annals of Pediatric Surgery.* 2007; 3: 41-3.
- Kalantari M, Mousavi SA, Ahmadi J, Nahvi H, Poorang H and Mehrabi V. The primary results of tubularized incised plate hypospadias repair in Markaz Tebbi and bahrami hospital. *Tumj.* 2005; 63:120-23.
- Borer JG, Bauer SB, Peters CA, Diamond DA, Atala A, Cilento BG Jr, et al.: Tubularized incised plate urethroplasty: expanded use in primary and repeat surgery for hypospadias. *J Urol.* 2001; 165: 581-5.
- Ziada AM, Morsi H, Aref A, Elsaied W: Tubularized incised plate (TIP) in previously operated (redo) hypospadias. *J Pediatr Urol.* 2006; 2: 409-14.
- Gozar H, Gliga V, Borda A, Turcu M: Review of Cases Operated with Snodgrass Technique. *JPSS.* 2009; 3: 32-5.
- Cakan M, Yalçinkaya F, Demirel F, Aldemir M, Altuğ U: The midterm success rates of tubularized incised plate urethroplasty in reoperative patients with distal or midpenile hypospadias. *Pediatr Surg Int.* 2005; 21: 973-6.
- Mousavi SA, Mohammadjafari H: Circumcision with the plastibell device in hooded prepuce or glanular hypospadias. *Adv Urol.* 2009; 864816.
- Pieretti RV, Pieretti A, Pieretti-Vanmarcke R: Circumcised hypospadias. *Pediatr Surg Int.* 2009; 25: 53-5.
- Mousavi SA: Use of tubularized incised plate urethroplasty for secondary hypospadias repair or repair in circumcised patients. *Int Braz J Urol.* 2008; 34: 609-14; discussion 614-6.
- El-Sherbiny MT, Hafez AT, Dawaba MS, Shorrab AA, Bazeed MA: Comprehensive analysis of tubularized incised-plate urethroplasty in primary and re-operative hypospadias. *BJU Int.* 2004; 93: 1057-61.
- Subramaniam R, Spinoit AF, Hoebeke P: Hypospadias repair: an overview of the actual techniques. *Semin Plast Surg.* 2011; 25: 206-12.
- Snodgrass W, Ziada A, Yucel S, Gupta A: Comparison of outcomes of tubularized incised plate hypospadias repair and circumcision: a questionnaire-based survey of parents and surgeon. *J Pediatr Urol.* 2008; 4: 250-4.
- Akbiyik F, Tiryaki T, Senel E, Mambet E, Livanelioglu Z, Atayurt H: Clinical experience in hypospadias: results of tubularized incised plate in 496 patients. *Urology.* 2009; 73: 1255-7.
- Sarhan OM, El-Hefnawy AS, Hafez AT, Elsherbiny MT, Dawaba ME, Ghali AM: Factors affecting outcome of tubularized incised plate (TIP) urethroplasty: single-center experience with 500 cases. *J Pediatr Urol.* 2009; 5: 378-82.
- Bush NC, Holzer M, Zhang S, Snodgrass W: Age does not impact risk for urethroplasty complications after tubularized incised plate repair of hypospadias in prepubertal boys. *J Pediatr Urol.* 2013; 9: 252-6.

27. Snodgrass W: Changing concepts in hypospadias repair. *Curr Opin Urol.* 1999; 9: 513-6.
28. Eliçevik M, Tireli G, Demirali O, Unal M, Sander S: Tubularized incised plate urethroplasty for hypospadias reoperations in 100 patients. *Int Urol Nephrol.* 2007; 39: 823-7.
29. Yang SS, Chen SC, Hsieh CH, Chen YT: Reoperative Snodgrass procedure. *J Urol.* 2001; 166: 2342-5.
30. Akal HA. Tubularized incised plate urethroplasty (snodgrass) for hypospadias reoperation. *Bas J Surg.* 2006; 12: 88-9.

---

**Correspondence address:**

Seyed A. Mousavi  
Department of Pediatric Surgery,  
Booali Sina Hospital, Pasdaran Boulevard, Sari,  
Mazandaran Province, Iran sari 48178-46859  
Iran, Islamic Republic of  
E-mail: dr.a.mosavi@gmail.com