



Two-handed assisted laparoscopic surgery: Evaluation in an animal model

Eduardo Sanchez-de-Badajoz, Pilar Sanchez-Gallegos, Jose Manuel Martinez-Moreno

Department of Surgery, School of Medicine, Malaga, Spain

ABSTRACT

Purposes: To evaluate in an animal model the feasibility of a novel concept of hand-assisted surgery consisting of inserting two hands into the abdomen instead of one. The chosen procedure was retroperitoneal lymph node dissection (L-RPLND) that was performed in five pigs.

Surgical Technique: A Pfannestiel and a transverse epigastric incisions were made through which both hands were introduced. The scope was inserted through the umbilicus. The colon was moved medially and the dissection was performed as in open surgery using short conventional surgical instruments.

Comments: The surgery was fulfilled easily and safely in quite a similar way as in open surgery. Two-handed laparoscopy may be indicated in cases that still today require an open approach as apparently makes the operation easier and significantly shortens the surgery time. However, new opinions and trials are required.

ARTICLE INFO

Key words:

Laparoscopy; Medical Oncology; Kidney Neoplasms

Int Braz J Urol. 2014; 40: 697-701

Submitted for publication:
March 23, 2014

Accepted after revision:
May 22, 2014

INTRODUCTION

Hand assisted laparoscopic surgery represented a giant step and made the technique available to almost anyone, greatly facilitating kidney surgery. When hand assisted laparoscopic surgery was introduced, in the mid nineties, it seemed that laparoscopy would have no limits. However, despite the great advances made, the early expectations have failed to be realized and there are now new frontiers that are difficult to overcome, or at least the price of doing so may be high, in terms of possible complications or surgical time.

Large renal tumors are difficult to manage, or a tumor thrombus in the vena cava, which, except very rarely, requires open surgery (1,2). La-

paroscopic nephrectomy for polycystic kidneys is also difficult, particularly in bilateral cases where the operative time even in expert hands is 5 to 6 hours (3). Though partial nephrectomy is fairly standardized, in large tumors located in the central area the procedure is complicated. Bilateral cases usually require surgery in two times, and when done in a single procedure the operation can be excessively long as well as easily requiring 9 trocars (4). Surgery of the adrenal gland, especially if it is bilateral, is also complex (5). Surgery like transuretero-ureterostomy (6), retrocaval ureter (7), retroperitoneal fibrosis (8) or primary retroperitoneal tumors are also difficult (9). Retroperitoneal lymph node dissection (RPLND) due to testicular cancer, though performed laparoscopically, is a challenging operation and its

great complexity result in open surgery being the choice method at most centers (10). In these procedures, that are at the limit of the possibilities of laparoscopy, apart from their inherent difficulty, time is unacceptably long even in experienced hands. In obese patients surgery, especially laparoscopic surgery, is also difficult. Likewise, in previously operated patients there is no anatomy and the difficulty is multiplied greatly.

Herein we investigate in five pigs the possibilities of a technique that consists in inserting in the abdomen not just one but both hands, that may be indicated in those cases that still require a large incision or involve much difficulty when done laparoscopically. The chosen procedure is a laparoscopic non-nerve sparing retroperitoneal lymph node dissection (L-RPLND). The reason to do it in that particular procedure is because it is easily reproducible in an animal model and also is an approach that is potentially applicable in a wide variety of surgeries.

SURGICAL TECHNIQUE

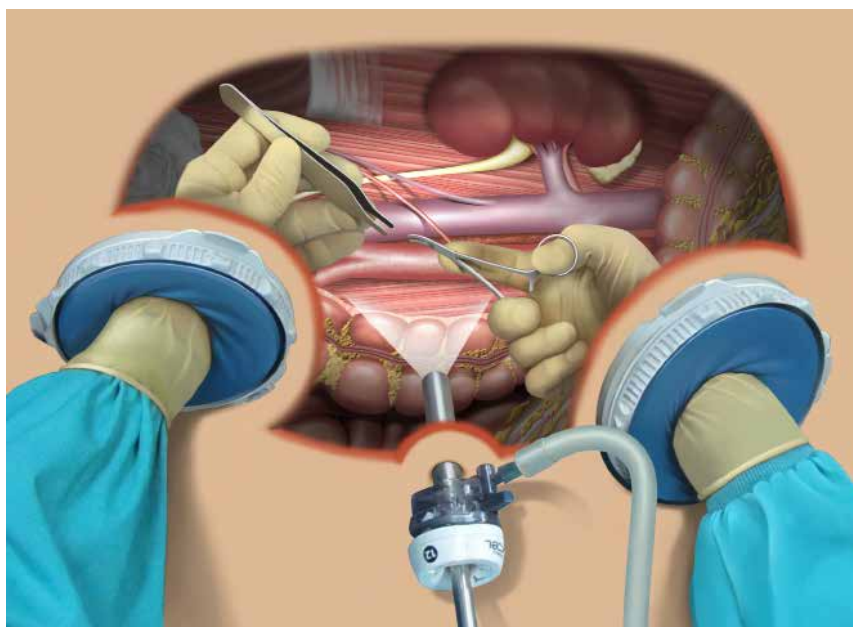
Five male “Large White” pigs with a nominal body weight between 45 and 60 kg were

used. The animals were given telazol 4.4mg/kg, ketamine 2.2mg/kg, and xylazine 2.2mg/kg for induction of general anesthesia. Anesthesia was maintained with isoflurane 3% during the procedure. No follow-up was done and at the end of the procedure they were euthanized.

Surgical procedure

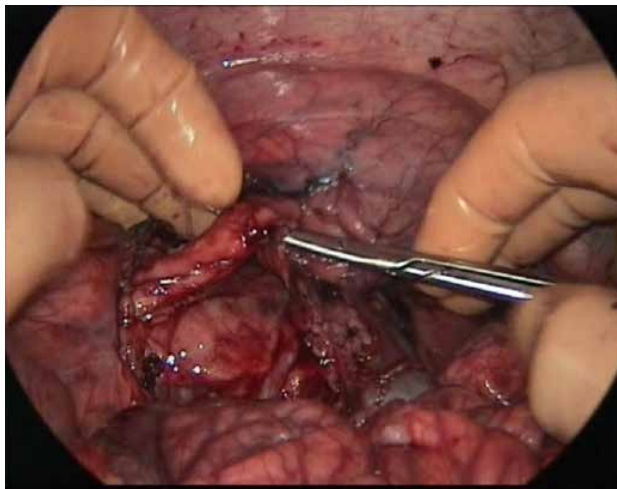
After positioning the pig in left lateral decubitus, a Pfannestiel skin incision is made and a handport is placed. Then a transverse skin incision is made in the epigastrium, followed by separation of the two rectus abdominis muscles and a second handport is placed. Between the two incisions, through the umbilicus, a trocar with a 30° scope is inserted (Figure-1). No laparoscopy instruments are used for this surgery, but rather conventional instruments are utilized, which are all introduced via the handports. In the left hand an Adson forceps is hold and in the right a short dissecting clamp which is alternated with scissors or swabs for blunt dissection. In order not to be constantly inserting and withdrawing the instruments, the ones not being used including swabs are placed on the liver that is used as a kind of shelf.

Figure 1 - Both hands have been introduced, the ascending colon has been displaced medially and the lymph node dissection is been carried out with shorts conventional instruments.



The procedure is started by addressing the right kidney, identifying its vein, artery and the ureter. Then the vena cava is dissected from the renal vein to the iliac vessels, separating it from the aorta. Then a vascular tape is passed underneath it and the lumbar veins are ligated one-by-one with a 0 silk suture (Figure-2). Then, without changing the position of the patient, the aorta artery is addressed. The left renal vein and artery are dissected. The dissection is continued caudally, finishing the separation of the artery from the vena cava down to

Figure 2 - The ureter is been shown. At the bottom, in between the hands, is the right kidney covered by the peritoneum.



the iliac vessels, identifying the hypogastric plexus which in this study is not preserved. The lumbar arteries and the inferior mesenteric artery are divided and ligated. Simultaneously all the lymph vessels that are found are resected. These sutures are not inserted via the handports, since abdominal pressure and time would both be lost, but rather the scope is withdrawn and the thread is introduced blindly via the scope trocar and then the ligature is performed with both hands.

Finally, a hand is passed underneath the aorta and the vena cava in order to confirm the complete dissection from the renal hilus to the start of the iliac vessels.

COMMENTS

In one case the endotracheal tube was badly placed and air entered the intestine, inflating

the loops. Though this increased significantly the difficulty of the operation, the procedure could be finished and the animal remained alive until just a few minutes before the end. Intubation in the pig is difficult and long blade laryngoscopes are usually necessary, more so with larger animals. The animals of this study were large and therefore the intubation was complicated. In another case the inferior mesenteric artery was inadvertently cut. The resulting hemorrhage was resolved by holding the artery with the left hand, placing a clamp with the right hand and doing the ligature. In no case the great vessels were injured nor was there any accident with the lumbar arteries or veins. The operative time ranged from 195 to 255 minutes.

In the era of minimally invasive surgery this technique may look a step backward, but the fact is that still today an important part of the urological surgery should be done in a conventional way. This procedure should not be done when regular laparoscopy could be used in a safe and reliable way. In reality, it does not intend to compete with standard laparoscopy, but to be used in cases that still require a big incision. And in those cases, we do believe that our approach is innovative because it may minimize significantly the invasiveness and harm done to the patient.

The technique described here is not really two-hand assisted laparoscopy, but rather it is laparoscopic surgery done wholly with both hands. Use of the handport is important. We have been performing hand assisted surgery for years, introducing the hand directly and we have to admit that this type of surgery using both hands is difficult without the use of the hand devices. The scope should be placed via the umbilicus and should involve a 30° lens. A zero degrees rigid scope would not enable proper vision beyond the intestinal loops.

Only two incisions are required for the hands and a puncture for the scope. All the instruments are introduced via the hand incisions and no more punctures are normally required because retractors are not necessary, as there is no abdominal wall or wound edges that hinder access and vision. The ideal patient for this procedure would be corpulent and the ideal surgeon

should have a small hand. The preferred working area, rather than the pelvis, is the upper abdomen or lumbar region, which are where greater incisions are needed and the wounds more mutilating.

This type of surgery could be said not to be warranted when the sum of the two incisions is equal to or greater than that of a single incision. However, it seems that two small incisions are preferable to one long incision, but that has yet to be proved. Moreover, as compared with lumbotomy, a Pfannestiel incision is less traumatic, less painful, more esthetic and involves less risk of developing a hernia. In a lumbotomy three layers of muscle are hurt and very often the iliohypogastric and ilioinguinal nerves are damaged; that results in abdominal asymmetry and disfiguration due to lack of muscle tone, an injury that often remains for the rest of the patient's life.

The handports should not be very near the actual site of surgery. To approach the kidney and great vessels, the ideal site for the handports is the hypogastrium, making a Pfannestiel incision, and the epigastrium, also making a transverse incision or longitudinal depending on surgeon preferences. This location for the scope and the handports also enables the surgeon to work, if necessary, on the opposite side with no need for any additional incision. If required, an extra 5mm trocar could be placed in the lumbar region to insert an aspirator for example, though this was not necessary in our series because we keep the surgical field clean and dry with swabs.

This surgery, apart from the telescope, does not require any laparoscopic devices, but just instruments used in conventional surgery, such as dissection forceps, mosquito clips, curved dissecting clamps, short blunt scissors or short Satinski clamps. As these instruments are all short the precision is increased, because the tactile sensation is far superior from that with laparoscopic instruments measuring at least 35cm long. However, that surgery may allow the design of new instruments that would fit better to the working conditions of that type of operations.

Although the ligatures were done manually, it is also possible to use short open surgery

staplers introduced via the handport. This would reduce the surgical time considerably. For the same reason, short conventional electric scissors could be perhaps very helpful. For a tumor thrombus in the vena cava or any other situation that requires suturing at a difficult site like the vena cava, having both hands in the surgical field may be a significant aid.

Complex surgery such as this can be done by just one surgeon with both hands, without the need for an assistant in the operating field, for the simple reason, we hardly need to retract or separate, as the gas creates a working field involving the whole abdominal cavity, with the intestinal loops being displaced and kept apart by gravity. The feeling is very different to that found in open surgery, where the surgeon has to place his hands as if they were almost to the bottom of a pit. This surgery can be compared to bench surgery, in which the organ is extracted, placed on a working bench, comfortably repaired and then replaced.

The concept of laparoscopic surgery with both hands inside the abdomen is different to what we are accustomed to, because instrumental laparoscopy requires much training. Laparoscopic surgery is much easier assisted with one hand, though it is still as though the surgeon only had one arm, which explains the associated limitations. Two-handed laparoscopic surgery, though, allows the operator to work under excellent conditions. Furthermore, should there be a mishap, like a hemorrhage, having both hands available enables the surgeon to resolve the situation more easily and more safely. Two-handed laparoscopic surgery can have many undescribed indications, in the fields of gastrointestinal and obesity surgery, gynecology, vascular surgery, and why not thoracic surgery? It could also be used in orthopedic surgery for the transperitoneal approach to the lumbar spine.

The surgical field of view is excellent and a retractor is not needed, because the organs mostly separate themselves alone through the force of gravity. Thus, in comparison with open surgery, the justification is that two-handed laparoscopic surgery not only reduces the size of the incision, it also considerably improves the

field of view, hardly restricting the surgeon. Thus, laparoscopy has well-defined limits that will be difficult to surpass. These limits relate in great part to the incomplete tactile sensation afforded to the surgeon. For the time being, some of these limits could be overcome in select cases by two-handed laparoscopic surgery. Nevertheless, new studies and trials are required before its general use could be recommended.

CONFLICT OF INTEREST

None declared.

REFERENCES

1. Conley SP, Humphreys MR, Desai PJ, Castle EP, Dueck AC, Ferrigni RG, et al.: Laparoscopic radical nephrectomy for very large renal tumors (> or =10 cm): is there a size limit? *J Endourol.* 2009; 23: 57-61.
2. Abaza R: Initial series of robotic radical nephrectomy with vena caval tumor thrombectomy. *Eur Urol.* 2011; 59: 652-6.
3. Lee DI, Clayman RV: Hand-assisted laparoscopic nephrectomy in autosomal dominant polycystic kidney disease. *J Endourol.* 2004; 18: 379-82.
4. Ching CB, Li J, Gill IS, Simmons MN: Functional and oncologic outcomes of bilateral open partial nephrectomy versus bilateral laparoscopic partial nephrectomy. *J Endourol.* 2011; 25: 1193-7.
5. Castillo OA, López-Fontana G, Vitagliano G: Laparoscopic synchronous bilateral adrenalectomy. *Arch Esp Urol.* 2011; 64: 114-20.
6. Piaggio LA, González R: Laparoscopic transureteroureterostomy: a novel approach. *J Urol.* 2007; 177: 2311-4.
7. Dogan HS, Oktay B, Vuruskan H, Yavascaoglu I: Treatment of retrocaval ureter by pure laparoscopic pyelopyelostomy: experience on 4 patients. *Urology.* 2010; 75: 1343-7.
8. Srinivasan AK, Richstone L, Permpongkosol S, Kavoussi LR: Comparison of laparoscopic with open approach for ureterolysis in patients with retroperitoneal fibrosis. *J Urol.* 2008; 179: 1875-8.
9. Vitagliano G, Ameri C: [Laparoscopic management of a retroperitoneal tumor: case report and literature review]. *Arch Esp Urol.* 2009; 62: 663-7.
10. Benway BM, Diaz DL, Katz MD, Vardi IY, Chavla NT, Desai AC, et al.: Open versus laparoscopic retroperitoneal lymph node dissection: assessing adequacy of dissection in a porcine model. *J Endourol.* 2009; 23: 485-8.

Correspondence address:

Eduardo Sanchez-de-Badajoz, MD
 Department of Surgery, School of Medicine
 Boulevard Louis Pasteur, 32. Malaga 29071
 Malaga, 29071, Spain
 Fax: + 34 952 609-567
 E-mail: sbadajoz@gmail.com